Gastrointestinal Tumors

REVIEW

Open Access

https://doi.org/10.48130/git-0026-0013

Gastrointestinal Tumors **2026**, 13: e014

Application progress and prospects of artificial intelligence in early cancer of the digestive tract

Xuyulin Yang[1,2], Qian Li[1], Manli Cui[1], Chao Sun[3], Qingling Fan[1*] and Mingxin Zhang[1*]

[1] *Department of Gastroenterology, The First Affiliated Hospital of Xi'an Medical University, Xi'an 710077, China*
[2] *The Graduate School of Xi'an Medical University, Xi'an 710021, China*
[3] *Department of Gastroenterology and Hepatology, Tianjin Medical University General Hospital, Tianjin 300052, China*
* Correspondence: fql047605@163.com (Fan Q); zmx3115@163.com (Zhang M)

Abstract

Recent advances in AI have brought new promise for improving the early diagnosis of digestive tract tumors, including esophageal, gastric, and colorectal cancers, thereby enhancing patient prognosis. Traditional endoscopic screening heavily relies on operator expertise, leading to high miss rates and uneven resource distribution. AI, through deep learning algorithms, has demonstrated remarkable performance in endoscopic image recognition, pathological slide analysis, and clinical risk prediction, effectively increasing early lesion detection and reducing inter-observer variability. This review systematically summarizes the latest research on AI applications in endoscopic diagnosis and prognostic prediction for early digestive tract cancers, while also addressing the challenges of integrating these technologies into existing clinical workflows. By leveraging large-scale data analysis and intelligent decision-making, AI has the potential to transform early cancer management from an experience-driven paradigm to a data-intelligent one. However, large-scale prospective clinical trials are still required to validate its real-world clinical utility, facilitating standardized primary care and personalized screening strategies.

Keywords: Artificial intelligence, Early digestive tract cancers, Precancerous lesions, Endoscopic diagnosis, Quality control, Clinical prediction

Citation: Yang X, Li Q, Cui M, Sun C, Fan Q, et al. 2026. Application progress and prospects of artificial intelligence in early cancer of the digestive tract. *Gastrointestinal Tumors* 13: e014 https://doi.org/10.48130/git-0026-0013

Introduction

According to the GLOBOCAN 2020 statistics, digestive tract tumors are among the leading causes of cancer-related mortality worldwide. Colorectal cancer and stomach cancer rank highest, followed by esophageal cancer (EC)[1]. The long-standing challenge of low detection rates and high mortality rates for gastrointestinal tumors remains a significant health concern in China, with the vast majority of patients diagnosed at an advanced stage of the tumors[2]. The cornerstone for addressing these issues is proactive detection, early diagnosis, and effective treatment.

The primary diagnostic method is endoscopic identification combined with biopsy and pathological examination. However, these traditional screening modalities are highly dependent on the professional knowledge and experience of practitioners, resulting in a high probability of missed diagnoses, with an adenoma miss rate (AMR) exceeding 20%[3,4].

The surge in artificial intelligence (AI) has brought breakthroughs, with AI-assisted diagnostic technology developing rapidly in recent years. Using technologies such as Deep Learning (DL) and Computer Vision, AI has gradually been applied to practical scenarios, such as endoscopic diagnosis and clinical prediction[5]. AI technology facilitates technical support for addressing this issue through the precise extraction of lesion features via machine learning (ML) algorithms. Its core applications include computer-aided detection (CADe) and computer-aided diagnosis (CADx) systems, which are complementary in their technical positioning: CADe focuses on 'detecting lesions', enabling rapid localization of potential abnormalities through image analysis; CADx emphasizes 'characterizing lesions', clarifying their benign or malignant nature and risk level through multi-dimensional feature analysis[6,7].

Although several reviews have summarized AI applications in individual digestive cancers or specific endoscopic tasks, most remain focused on a single organ, a single imaging modality, or a single technical function. A comprehensive, cross-organ synthesis that integrates endoscopic diagnosis, pathological identification, endoscopy quality control, and clinical prediction for early digestive tract cancer is still lacking. Moreover, the gap between high-performance retrospective models and real-world clinical translation remains underexplored. This review therefore aims to: (1) provide a cross-organ, clinically oriented synthesis of AI applications in early esophageal, gastric, and colorectal cancer; (2) compare CADe, CADx, depth/margin assessment, and prognostic prediction; (3) critically appraise study design, validation status, and real-world performance; and (4) outline challenges and potential solutions for regulatory approval, clinical implementation, and primary care empowerment.

Advancement of AI technology

AI is a pivotal branch of computer science, and ML is a significant application field within AI, serving as the fundamental approach to endow computers with intelligence[8,9]. ML algorithms are broadly categorized into traditional methods (manual feature design) and DL methods, which autonomously extract and learn features from data[10].

Specifically, DL mimics the neural network structure of the human brain, using multiple hidden layers to improve classification or prediction accuracy and replace manual feature extraction (Fig. 1)[11]. Among various DL networks, convolutional neural networks (CNNs) excel at processing image and video data, including tasks such as image classification, object detection, and image segmentation[12]. Furthermore, several CNN-based models have been specifically designed for medical image segmentation, such as FCN and U-Net[13,14].

© The Author(s)

https://doi.org/10.48130/git-0026-0013

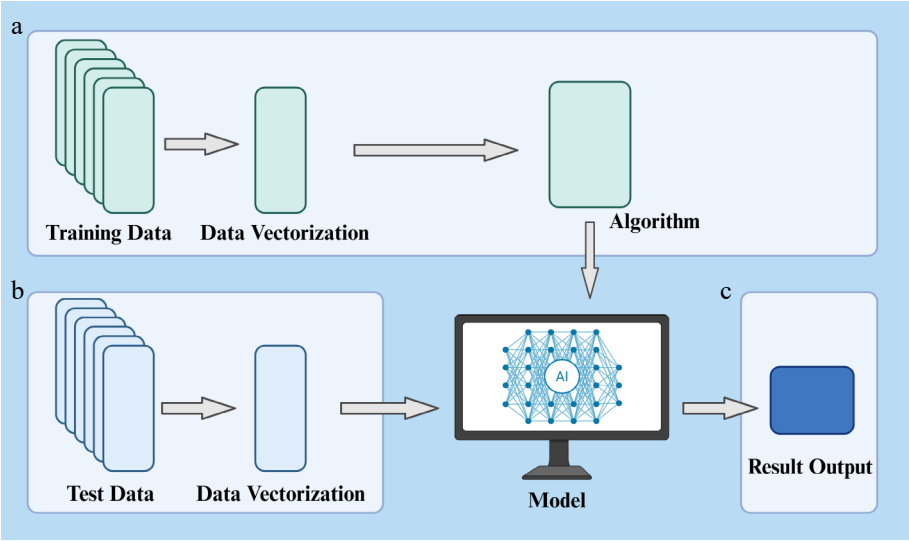

Fig. 1 Schematic diagram of the working principle of AI utilizing deep learning. (a) Training data: Expert-annotated training data are used to train the model. (b) Test data: A separate dataset is collected to evaluate model performance. (c) Result output: The model generates the final results. Created with BioRender.com.

In recent years, AI has advanced rapidly in the field of digestive endoscopy, demonstrating significant efficacy in auxiliary diagnostic tasks such as polyp detection, assessment of *Helicobacter pylori* infection status, differentiation of lesion characteristics, and evaluation of lesion extent[15]. AI can identify and accurately classify endoscopic images in real-time[16], positioning it as a 'third eye' for continuous monitoring of endoscopy quality[17]. Therefore, the integration of AI technology with digestive endoscopy offers significant potential to augment endoscopists in the detection and screening of early-stage cancerous lesions. It should be noted, however, that most performance metrics cited in this review were derived from retrospectively collected, expert-annotated datasets obtained under optimized imaging conditions. They should therefore be interpreted as proof of technical feasibility rather than established real-world effectiveness.

AI and early esophageal cancer

EC ranks seventh globally in incidence among malignant tumors and sixth in overall mortality rates[1,18]. Studies have shown that China's early diagnosis rate for EC ranged between 12.3% and 17.7% during 2015–2019[19]. EC comprises two primary histological types: esophageal squamous cell carcinoma (ESCC) and esophageal adenocarcinoma (EAC). Because early symptoms are nonspecific, most patients present at an advanced stage at symptom onset. Therefore, implementing screening programs to facilitate early diagnosis and treatment represents a crucial strategy for improving the EC prognosis[20]. However, the diagnosis of early EC remains heavily dependent on the practitioner's expertise, leading to significant variability in diagnostic proficiency across clinicians.

Integrating AI with endoscopic techniques can standardize these experience-dependent diagnostic processes, enabling practitioners to rapidly identify lesions and establish a diagnosis, thereby compensating for the limited clinical exposure often seen among general practitioners.

Identification of esophageal squamous cell carcinoma

ESCC represents the predominant histological subtype in developing countries, particularly China. Given the high incidence of ESCC in China, research teams from China, Japan, and other regions have increasingly focused on applying AI to diagnose early-stage ESCC[21,22]. Commonly employed clinical endoscopic techniques for detecting ESCC include white-light endoscopy (WLE), narrow-band imaging (NBI), blue laser imaging (BLI), iodine staining, and magnifying endoscopy (ME)[23]. Although WLI remains the most widely used screening modality, its sensitivity is heavily dependent on the operator's expertise. AI systems have been developed to augment detection capabilities, particularly for less experienced endoscopists (Table 1).

Detection of early-stage lesions

Cai et al.[24] utilized a dataset comprising 2,428 WLI images for training and 187 for testing, demonstrating that the diagnostic performance of their AI system was comparable to that of expert practitioners. Moreover, when assisted by the AI system, the diagnostic sensitivity of non-expert endoscopists improved significantly, underscoring the system's potential as an adjunct tool. In a multicenter study, Tang et al.[25] developed an AI system trained on 4,002 WLI images; this system achieved a sensitivity of 97.9% for detecting superficial ESCC on internal validation and maintained robust performance on external image and video datasets.

Despite these advances, single-modality systems are characterized by intrinsic limitations. Li et al.[26] compared an NBI-AI system with the previously reported WLI-AI system[24]. While the NBI-AI system showed superior accuracy and specificity, it had lower sensitivity than the WLI-AI system. Notably, the concurrent application of both systems yielded the highest diagnostic accuracy, suggesting that multimodal integration may optimize performance.

Subsequent research has focused on developing multimodal AI systems that integrate multiple endoscopic techniques. Horie et al.[27] first reported a dual-modality system integrating WLI and NBI, which accurately identified 98% of superficial EC, including lesions < 10 mm. More recently, Yuan et al.[28] developed a YOLO v3-based multimodal AI system integrating WLI, NBI, iodine staining, and ME for diagnosing superficial ESCC and precancerous lesions. Using 45,770 images for training and testing, 6,075 internal validation images, and 2,088 external validation images from four hospitals, the system achieved significantly higher sensitivity than experienced practitioners in detecting epithelial-layer ESCC on WLI images (90.8% vs 82.5%).

Table 1. Application of AI in early ESCC.

Ref.	Country	Study type	Subjects	Model/ algorithm	Endoscope type	Sample size	Sensitivity (%)	Specificity (%)	Accuracy (%)	AUC
Cai et al.(2019)[24]	China	Retrospective, multicenter (2)	ESCC	DNN-CAD	WLI	Training set: 2,428 Validation set: 187	97.8	85.4	91.4	0.9637
Tang et al.(2021)[25]	China	Retrospective, multicenter (3)	ESCC	DCNN	WLI	Training set: 4,002 Validation set: 333/700	97.9	88.6	91.3	0.9540
Li et al.(2021)[26]	China	Retrospective, multicenter (3)	ESCC	CAD-NBI vs CAD-WLI	WLI/NM-NBI	Training set: 4,735 NM-NBI images Validation set: 316 pairs of WLI and NBI images	91.0	96.7	94.3	0.9761
Horie et al.(2019)[27]	Japan	Retrospective, single-center	ESCC	CNN	WLI/NBI	Training set: 8,428 Validation set: 1,118	98.0 (per-case)/77 (per-image)	79.0	98.0	NR
Yuan et al.(2022)[28]	China	Retrospective, multicenter (5)	ESCC	YOLO v3 (DCNN)	WLI/NBI/ iodine staining/ME	Training set: 45,770 Validation set: 6,075 (Internal)/2,088 (External)	Internal cohort: 96.9 External cohort: 97.2	Internal cohort: 83.1 External cohort: 82.3	Internal cohort: 91.1 External cohort: 91.2	Internal cohort: 0.9510 External cohort: 0.9460
Nakagawa et al.(2019)[33]	Japan	Retrospective, single-center	ESCC	CNN	WLI/NBI/BLI	Training set: 8,660 non-ME/5,678 ME Validation set: 405 non-ME/509 ME	90.1	95.8	91.0	NR
Shimamoto et al.(2020)[34]	Japan	Retrospective, single-center	ESCC	CNN	WLI/NBI/BLI	Training set: 23,977 images Validation set: 102 video images	ME: 70.8 non-ME: 50.0	ME: 94.9 non-ME: 96.9	ME: 89.2 non-ME: 87.3	NR
Guo et al.(2020)[39]	China	Retrospective, single-center	ESCC	CAD	NBI	Training set: 6,473 Validation set: 175,536 images and video frames	98.04	95.03	NR	0.9890
Liu et al.(2022)[40]	China	Retrospective, multicenter (5)	ESCC	DCNN	WLI	Training set: 10,467 Validation set: 1,114 (Internal)/211 (External)	Internal cohort: 86.6 External cohort: 91.1	Internal cohort: 81.4 External cohort: 78.0	Internal cohort: 93.4 External cohort: 95.7	NR
Ikenoyama et al.(2021)[41]	Japan	Retrospective, single-center	ESCC	GoogleNet (CNN)	WLI/NBI	Training set: 6,634 Validation set: 667	84.4	70.0	76.4	NR

ESCC: esophageal squamous cell carcinoma. DNN: deep neural network. DNN-CAD: deep neural network-based computer-assisted detection. DCNN: deep convolutional neural network. CAD-NBI: computer-assisted detection for narrow-band imaging. CAD-WLI: computer-assisted detection for white-light imaging. CAD: computer-assisted detection. CNN: convolutional neural networks. WLI: white-light imaging. NM-NBI: non-magnifying endoscopy with narrow-band imaging. NBI: narrow-band imaging. BLI: blue laser imaging. ME: magnified endoscopy. AUC: area under the curve. NR: not reported. The original study did not explicitly state this information. 'Validation set' indicates that the original study utilized a validation cohort but did not explicitly define it as internal (e.g., data split) or external (e.g., independent institution). The values in parentheses indicate the specific data of each center.

Collectively, these studies underscore that multimodal AI systems, by mimicking the endoscopist's workflow, offer greater clinical utility. While they hold promise to become a standard adjunct for AI-assisted early ESCC detection, prospective randomized controlled trials are still warranted to confirm their clinical efficacy.

Identification of the depth of penetration

Accurate determination of tumor invasion depth represents a critical decision point that dictates therapeutic strategy: endoscopic treatment for EP-LPM lesions vs surgery or chemoradiotherapy for SM2 and deeper lesions[29]. Currently, the method proposed by the Japanese Esophageal Society, based on the endoscopic observation and classification of intrapapillary capillary loops (IPCL) morphology, has become the primary approach for assessing the invasion depth of early-stage EC[30,31]. However, its reliable application demands substantial expertise that is not universally available. Consequently, there is a need for a more advanced measurement approach that enables non-experts to achieve diagnostic quality equivalent to that of experts.

AI has emerged as a tool to bridge this expertise gap. Multiple studies have demonstrated that AI systems can assess invasion depth with accuracy comparable to—and in some cases exceeding—that of experienced endoscopists. Early models using non-magnified images demonstrated potential[32], but the integration of ME significantly improved performance. Nakagawa et al.[33] trained an AI system on 8,660 non-magnified and 5,678 magnified images (including WLI, NBI, and BLI), achieving diagnostic accuracies exceeding 90% for both EP-SM1 and SM2-3 lesions, which was comparable to the performance of 16 expert endoscopists.

The transition from static images to real-time video analysis marks a pivotal advancement. In 2020, Shimamoto et al.[34] pioneered the development of an AI system capable of assessing invasion depth from endoscopic videos, which achieved diagnostic accuracies of 87.3% (non-magnified) and 89.2% (magnified) for SM2-3 lesions. Notably, the system's performance exceeded that of 14 endoscopy specialists (84.7% and 84.4%, respectively), demonstrating that AI can not only match but potentially exceed human expert performance in dynamic clinical scenarios.

AI-assisted depth assessment offers real-time decision support for non-specialist endoscopists, potentially mitigating the risks of overtreatment (unnecessary surgery for endoscopically resectable lesions) and undertreatment (incomplete resection of deeper lesions). Notably, while the system did not enhance the diagnostic process, current evidence is largely derived from retrospective datasets. As these systems continue to evolve and undergo prospective validation, they show potential to democratize expertise in depth assessment across diverse clinical settings.

Identification of lesion margins

Precise preoperative assessment of lateral tumor extent is essential to ensure complete resection and minimize the risk of post-endoscopic strictures[35], particularly when lesions involve more

https://doi.org/10.48130/git-0026-0013

than two-thirds of the esophageal circumference[36]. Therefore, assessing the circumferential extent of the lesion prior to treatment is strongly recommended[37]. Iodine staining remains the clinical gold standard for margin delineation, but it is associated with patient discomfort, the risk of iodine allergy, and potential false positives due to inflammation[38].

AI offers a non-invasive alternative; for instance, Guo et al.[39] trained an AI system on a dataset of 6,473 magnified and non-magnified NBI images to predict lesion characteristics and extent. The system's performance in delineating superficial ESCC and precancerous lesions was comparable to that of experienced endoscopists. However, NBI is not available in all screening settings. Addressing this gap, Liu et al.[40] developed a DCNN-based AI system, trained on 10,467 WLI images and externally validated on 890 WLI images sourced from four hospitals. The system achieved 84.5% diagnostic accuracy for superficial ESCC and precancerous lesions, and its margin delineation accuracy (98.1%) was comparable to that of specialists (95.3%) and significantly exceeded that of senior physicians (78.6%).

Furthermore, AI can reduce the reliance on routine iodine staining. Ikenoyama et al.[41] developed an AI system capable of identifying patchy iodine-unstained mucosa from WLI and NBI images, thereby pinpointing high-risk individuals for ESCC without subjecting patients to the discomfort of chromoendoscopy. The AI system demonstrated higher sensitivity in detecting such mucosal changes than that of experienced practitioners. These advances suggest that AI may serve as a reliable, patient-friendly tool for preoperative margin mapping.

Identification of esophageal adenocarcinoma

EAC is highly prevalent in Western countries, yet in recent years, its incidence in China has demonstrated a consistent upward trend. Barrett's metaplasia refers to the development of cylindrical epithelial metaplasia in the squamous epithelium at the esophageal-gastric junction, representing a precancerous condition for EAC. It may progress to high-grade intraepithelial neoplasia or even invasive EAC. Most patients with EAC are diagnosed at an advanced stage, exhibiting a 5-year survival rate of less than 20%[42]. Therefore, early diagnosis of EAC is crucial. However, early-stage EAC or its precancerous lesions typically present as flat lesions with subtle morphology, making them difficult to distinguish from surrounding cylindrical epithelial metaplasia. This poses significant challenges even for experienced endoscopists utilizing high-definition endoscopy. AI has emerged as a powerful tool to address this challenge by enhancing lesion detection and characterization during endoscopic surveillance (Table 2).

Lesion detection and localization

Early AI systems for Barrett's esophagus (BE)/EAC detection focused on improving lesion recognition under standard WLI. Van der Sommen et al.[43] developed a CAD system using texture analysis on WLI images, achieving a sensitivity and specificity of 83% for detecting early neoplastic lesions in BE in a dataset of 44 patients. Subsequent DL approaches have significantly advanced in this field. Ghatwary et al.[44] applied CNNs to WLI images. Upon comparing four DL algorithms (R-CNN, Fast R-CNN, Faster R-CNN, and SSD), they determined that the SSD approach yielded superior performance in the automatic identification of endoscopic images indicative of EAC. They reported achieving a sensitivity of 96% and specificity of 92% for detecting early-stage EAC.

The Argos project has systematically advanced the field through a series of studies. De Groof et al.[45] initially developed a CAD system based on high-definition white light endoscopy (HD-WLE), which demonstrated promising performance in detecting early Barrett's neoplasia, yielding an accuracy, sensitivity, and specificity of 89%, 90%, and 88%, respectively. In a subsequent large-scale multicenter study, this research team trained a DL system. It demonstrated that it achieved high accuracy in detecting neoplasia, approaching the performance of expert pathologists and outperforming general endoscopists. This study also underscored the system's potential to reduce interobserver variability in BE surveillance. Further refinement using multi-stage domain-specific pretraining—involving initial training on a large corpus of endoscopic images followed by fine-tuning on BE-specific data—improved generalization to external datasets[46].

Table 2. Application of AI in BE and EAC.

Ref.	Country	Study type	Subjects	Model/ algorithm	Endoscope type	Sample size	Sensitivity (%)	Specificity (%)	Accuracy (%)	AUC
Van der Sommen et al.(2016)[43]	The Netherlands	Retrospective, single-center	BE	CAD	WLI	Training set: 100 Validation set: leave-one-out cross-validation on a per-patient basis	83.0	83.0	NR	NR
Ghatwary et al.(2019)[44]	UK	Retrospective, NR	BE, EAC	SSD (CNN)	HD-WLE	Training set: 21 patients Validation set: 9 patients	96.0	92.0	NR	NR
De Groof et al.(2020)[45]	The Netherlands	Retrospective, multicenter (4)	BE	CAD	HD-WLE	Training set: 494,364 Validation set: 1,704	90.0	88.0	89.0	NR
Hashimoto et al.(2020)[51]	USA	Retrospective, single-center	BE, EAC	Xception + YOLO v2 (CNN)	WLI/NBI	Training set: 1,374 Validation set: 458	96.4	94.2	95.4	NR
Abdelrahim et al.(2023)[49]	UK	Prospective, multicenter (4)	BE	CAD	HD-WLE	Training set: 1,090,171 Validation set: 471 images/75 videos	Image: 95.3 Video: 93.8	Image: 94.5 Video: 90.7	Image: 94.7 Video: 92.0	Image: NR Video: 0.948

BE: barrett's esophagus. EAC: esophageal adenocarcinoma. CAD: computer-assisted detection. CNN: convolutional neural networks. SSD: single-shot multibox detector. HD-WLE: high-definition white light endoscopy. WLI: white-light imaging. NBI: narrow-band imaging. AUC: area under the curve. NR: not reported. The original study did not explicitly state this information. 'Validation set' indicates that the original study utilized a validation cohort but did not explicitly define it as internal (e.g., data split) or external (e.g., independent institution). The values in parentheses indicate the specific data of each center.

The diagnostic yield is further enhanced by incorporating advanced imaging modalities. NBI enhances the visualization of mucosal and vascular patterns. Furthermore, it has been utilized in the development of an AI system specifically designed for analyzing the histological features of BE, achieving a diagnostic sensitivity of 88%[47].

Notably, multimodal AI systems—trained on combined datasets of WLI, NBI, and BLI—have consistently demonstrated an average sensitivity exceeding 90% for the identification of neoplastic lesions in BE[48–50]. However, these esophageal AI studies were mostly based on high-quality WLI, NBI, or magnified images from expert centers; in real-world practice, performance may decrease because of non-ME, mucus, peristalsis, motion artifacts, and inter-device variability.

From real-time detection to clinical integration: augmenting endoscopic practice

Beyond static image analysis, recent advances have crucially focused on integrating AI into real-time endoscopic practice to augment clinical decision-making directly. Hashimoto et al.[51] developed and validated a real-time AI system capable of detecting early esophageal neoplasia in BE during ongoing endoscopic procedures. The system achieved high diagnostic accuracy with a processing speed compatible with clinical workflows, demonstrating the technical feasibility of real-time AI assistance. Similarly, Abdelrahim et al.[49] conducted a multicenter pragmatic nonrandomized trial validating a real-time video-based CAD system for BE, which significantly outperformed nonexpert endoscopists and further showed that integrating AI into real-time endoscopic practice can directly augment clinical decision-making. The clinical value of this capability is profound. By flagging suspicious areas in real time, the system allows endoscopists to shift from the conventional random biopsy protocol (Seattle protocol) to a more precise, targeted biopsy approach. This paradigm shift has the potential to significantly reduce the sampling error inherent in current surveillance strategies, directly addressing a major clinical limitation.

The clinical integration of AI-assisted surveillance extends beyond improved lesion detection. By providing a continuous, real-time risk assessment overlay on the endoscopic video stream, AI systems can help standardize surveillance quality across different practice settings. This capability is particularly critical for reducing interobserver variability, a longstanding challenge in BE surveillance[52]. For general endoscopists with less experience in identifying subtle dysplastic changes, the AI serves as a real-time preceptor, potentially elevating their diagnostic performance toward that of experts. Consequently, AI integration is poised not merely to act as a detection tool, but as a powerful platform for quality assurance and skills standardization in routine endoscopic practice.

AI and early gastric cancer

Gastric cancer is one of the most common malignant tumors worldwide. The 5-year postoperative survival rate for early gastric cancer (EGC) can reach 95%, whereas that for advanced gastric cancer (AGC) stands at merely 30%[50,53]. In light of this, the early detection, diagnosis, and radical resection of gastric cancer constitute vital measures for reducing mortality rates. Histologically, gastric cancer is characterized by significant histological heterogeneity, with adenocarcinoma representing the predominant subtype (accounting for over 90% of cases). At the same time, other types such as gastrointestinal stromal tumors (GISTs), lymphomas, and neuroendocrine tumors are considerably less frequent and are associated with distinct biological behaviors and clinical management strategies[54]. Given its epidemiological predominance and the pivotal role of endoscopic screening in early detection, this section focuses on gastric adenocarcinoma and its precursor conditions.

Conventional WLI endoscopy has been extensively employed for screening and diagnosing gastric diseases[55]. Although the advent of endoscopic imaging techniques such as NBI, ME, laser confocal imaging, and cytoscopic endoscopy has effectively improved the diagnostic rate of early gastric lesions[56,57], the detection rate for EGC remains low[58,59]. The primary reason is that some practitioners lack experience in identifying EGC, resulting in the oversight of EGC lesions[5]. A multicenter cohort study indicated that endoscopic biopsy rates varied considerably between different practitioners (ranging from 22.4% to 52.9%) and were negatively correlated with gastric cancer detection rates[60].

Furthermore, certain EGC lesions exhibit morphological similarities to benign conditions such as superficial gastritis, gastric ulcers, and gastric polyps, rendering differentiation challenging. Small lesion size, inadequate expansion of the gastric mucosal cavity, and superficial or insufficient biopsy sampling are also contributing factors[61,62]. Therefore, practitioners must undergo extensive specialized training and accumulate substantial clinical experience to acquire the proficiency required to identify EGC[63]. Limited numbers of practitioners and their experience in diagnosing and treating early-stage cancers, coupled with China's large population, high patient volume, and equipment shortages, make it difficult to improve EGC detection rates. Consequently, AI-assisted diagnosis is regarded as the key technology to overcome the challenges in diagnosing EGC and facilitate the democratization of expertise (Table 3).

Identification of early-stage gastric cancer

Several AI systems have been developed to augment EGC detection. Tang et al.[64] trained a deep convolutional neural network (DCNN) system using WLI images. In the retrospective analysis, the system achieved accuracy of 85.1%–91.2%, sensitivity of 85.9%–95.5%, specificity of 81.7%–90.3%, and an AUC of 0.887–0.940. As an auxiliary tool, it significantly improved endoscopists' detection capability, increasing sensitivity from 82.7% to 94.7%.

Although static image analysis offers significant benefits, real-time video assessment remains critical for clinical practice. Wu et al.[65] employed a DCNN with ME to construct a model for dynamic video analysis. The DCNN achieved 92.5% accuracy, 94.0% sensitivity, 91.0% specificity, 91.3% positive predictive value (PPV), and 93.8% negative predictive value (NPV) for EGC detection, surpassing the performance of endoscopists across all experience levels. Building on this work, the same group developed the EndoAngel system, an AI-assisted diagnosis system for digestive endoscopy based on WLI, which enables real-time monitoring of blind spots and lesion detection. In a multicenter randomized controlled trial (RCT), EndoAngel significantly reduced blind spots and demonstrated an accuracy of 84.7%, a sensitivity of 100%, and a specificity of 84.3% in detecting EGC. These findings demonstrate that EndoAngel is an effective and robust system with the potential to enhance the quality of endoscopic examinations. In this multicentre study, EndoAngel proved to be an effective and robust system for enhancing the quality of EGD, demonstrating its potential for real-time detection of EGC[66]. In parallel, NBI-based AI systems have shown high diagnostic performance. Tang et al.[67] developed a model using NBI images, which achieved an AUC of 0.888–0.951 on validation datasets and successfully identified all EGC patients in a video cohort.

https://doi.org/10.48130/git-0026-0013

Table 3. Application of AI in EGC.

Ref.	Country	Study type	Subjects	Model/ algorithm	Endoscope type	Sample size	Sensitivity (%)	Specificity (%)	Accuracy (%)	AUC
Tang et al.(2020)[64]	China	Retrospective, multicenter (4)	EGC	DCNN	WLI	Training set: 35,823 Validation set: Internal 9,417/External 1,514	85.9–95.5	81.7–90.3	85.1–91.2	0.887–0.940
Wu et al.(2019)[65]	China	Retrospective, single-center	EGC	DCNN	ME	Training set: 9,151 Validation set: 200	94.0	91.0	92.5	NR
Wu et al.(2021)[66]	China	Prospective, multicenter (5)	EGC	DCNN	WLI	NR	100.0	84.3	84.7	NR
Zou et al.(2022)[67]	China	Retrospective, multicenter (5)	EGC	DCNN	NBI	Training set: 13,151 Validation set: 8,634 images/20 videos	87.7–96.7	81.1–91.3	86.0–92.9	0.888–0.951
Zhu et al.(2018)[72]	China	Retrospective, single-center	EGC	CNN-CAD	WLI	Training set: 5,056 Validation set: 1,264	76.47	95.56	89.16	0.940
Yoon et al.(2019)[73]	Korea	Retrospective, single-center	EGC	lesion-based VGG-16	WLI	Training set: 8,655–8,738 Validation set: 600	79.2	77.	NR	0.851
Nagao et al.(2020)[74]	Japan	Retrospective, single-center	EGC	WLI AI/NBI AI/Indigo AI	WLI/NBI/ 1% Indigo	Training set: WLI 8,271/NBI 2,701/ Indigo 2,656 Validation set: WLI 2,412/NBI 1,023/ Indigo 1,007	WLI: 84.4 NBI: 75.0 Indigo: 87.5	WLI: 99.4 NBI: 100.0 Indigo: 100.0	WLI: 94.5 NBI: 94.3 Indigo: 95.5	WLI: 0.959 NBI: 0.9048 Indigo: 0.9491
Bang et al.(2021)[75]	Korea	Prospective, single-center development, multicenter validation (2)	EGC	Neuro-T-based AutoDL	WLI	Training set: 2,609 Validation set: Internal 290/External 1,803	88.4	NR	89.3	NR
Goto et al.(2022)[76]	Japan	Retrospective, multicenter (2)	EGC	EfficientNetB1	WLI	Training set: 500 Validation set: 200	74.4	84.8	79.6	NR
Guimarães et al.(2019)[79]	Germany	Retrospective, single-center	CAG	VGG-16	WLI	Training set: 160 Test set: 70	100.0	87.5	92.9	0.981
Zhang et al.(2020)[80]	China	Retrospective, single-center	CAG	CNN-CAG	WLI	Training set: 3,829 Test set: 1,641	94.5	94.0	94.2	0.990
Horiuchi et al.(2020)[81]	Japan	Retrospective, single-center	Gastritis	CNN	ME-NBI	Training set: 2,570 Test set: 258	95.4	71.0	85.3	0.852
Shichijo et al.(2017)[86]	Japan	Retrospective, single-center	*Helicobacter pylori* infection	CNN	WLI	Training set: 32,208 Test set: 11,481	88.9	87.4	87.7	0.930
Itoh et al.(2018)[88]	Japan	Prospective cohort, single-center	*H. pylori* infection	DCNN	WLI	Training set: 596 Test set: 30	86.7	86.7	NR	0.956
Nakashima et al.(2018)[89]	Japan	Prospective, single-center	*H. pylori* infection	DCNN	WLI/BLI/LCI	Training set: 1,944 Test set: 180	WLI: 66.7 BLI: 96.7 LCI: 96.7	WLI: 60.0 BLI: 86.7 LCI: 83.3	WLI: 63.3 BLI: 91.7 LCI: 90.0	WLI: 0.660 BLI: 0.960 LCI: 0.960

EGC: early gastric cancer. CAG: chronic atrophic gastritis. DCNN: deep convolutional neural network. CNN: convolutional neural network. CAD: computer-assisted detection. CNN-CAD: convolutional neural network-based computer-assisted detection. CNN-CAG: convolutional neural network-based identification of chronic atrophic gastritis. VGG: Visual Geometry Group. WLI: white-light imaging. BLI: blue laser imaging. NBI: narrow-band imaging. ME: magnified endoscopy. ME-NBI: magnified endoscopy with narrow-band imaging. LCI: linked color imaging. AUC: area under the curve. NR: not reported. The original study did not explicitly state this information. 'Validation set' indicates that the original study utilized a validation cohort but did not explicitly define it as internal (e.g., data split) or external (e.g., independent institution). The values in parentheses indicate the specific data of each center.

These studies illustrate the evolution of AI-assisted EGC diagnosis from static image classification to real-time, multimodal endoscopic support, promising to democratize expertise and reduce miss rates.

Assessment of gastric cancer invasion depth

Thanks to advances in endoscopic diagnostic and therapeutic techniques, minimally invasive endoscopic therapy has become the preferred approach for lesions confined to the gastric mucosa or superficial submucosa. Therefore, accurately predicting the depth of invasion using endoscopic images is crucial for selecting patients suitable for endoscopic resection[68]. Currently, endoscopists primarily assess gastric cancer depth of invasion using WLI, chromoendoscopy, or endoscopic ultrasound. These three methods demonstrate comparable diagnostic accuracy for determining the depth of invasion, with reported rates ranging from 69% to 79%[69–71]. However, their effectiveness largely depends on the endoscopist's experience in recognizing endoscopic features of early lesions. Consequently, there is a clinical need for a more accurate and objective method to assess the depth of invasion in gastric cancer.

Zhu et al.[72] applied a CNN-CAD system to WLI images for depth prediction. The system achieved an AUC of 0.94, sensitivity of 76.47%, specificity of 95.56%, and overall accuracy of 89.16%, significantly exceeding the performance of endoscopists. This demonstrates the system's capability to distinguish EGC from deep submucosal infiltrating carcinoma while minimizing overestimation of invasion depth, thereby reducing the need for unnecessary gastrectomy. Yoon et al.[73] employed an AI system utilizing the VGG-16 model and WLI imaging to distinguish non-neoplastic lesions, T1a gastric cancer, and T1b gastric cancer. The study reported an AUC of 0.851 for predicting invasion depth. However, for histological subtypes, the AI demonstrated significant correlation and high accuracy only for well-differentiated carcinoma, whereas prediction accuracy was lower for poorly differentiated carcinoma. Therefore, further refinement and validation are required for undifferentiated carcinoma. Different endoscopic modalities may influence AI

performance. Nagao et al.[74] developed three independent AI systems to predict the depth of invasion of EGC based on WLI, NBI, and chromoendoscopy. Accuracy rates of 94.5%, 94.3%, and 95.5% were observed, respectively; the absence of statistically significant differences suggests that AI performs robustly across various imaging techniques. Bang et al.[75] conducted a multicenter prospective validation of an AI system for gastric cancer depth prediction, achieving 89.3% accuracy on external validation. Notably, while the system did not enhance the diagnostic performance of expert endoscopists, it demonstrated a significant benefit for trainees and non-specialists. However, further validation in diverse clinical environments is needed to confirm these findings.

In addition to standalone AI applications, human-AI collaboration has demonstrated synergistic effects. Goto et al.[76] developed an AI grading system to assist endoscopists in predicting gastric cancer invasion depth. In the collaborative setting, accuracy, sensitivity, and specificity reached 79.6%, 74.4%, and 84.8%, respectively, while the harmonic mean of PPV and sensitivity was 78.5%. These results significantly outperformed those of either standalone AI systems or endoscopists working independently, indicating that AI-endoscopist collaboration enhances diagnostic capability regarding the depth of invasion in EGC.

AI-assisted identification of precancerous lesions: chronic atrophic gastritis

Chronic atrophic gastritis (CAG) is a critical precursor lesion in the gastric carcinogenesis cascade[77]. The prevalence of CAG in China is markedly elevated, yet its diagnostic rate remains suboptimal, ranging from 17.7% to 25.8%[78]. Consequently, improving the concordance between endoscopic findings and histopathological diagnosis of CAG remains a significant clinical priority.

Guimarães et al.[79] trained a VGG-16 model using proximal gastric endoscopic images for diagnosing CAG. After validation, the model achieved 93% diagnostic accuracy for CAG with an AUC of 0.98, significantly outperforming endoscopists in all aspects. Similarly, Zhang et al.[80] collected 5,470 pathologically annotated gastric antrum images, of which 3,042 exhibited atrophic gastritis. The researchers designed and trained a CNN-CAG diagnostic model, achieving accuracy, sensitivity, and specificity of 94.2%, 94.5%, and 94%, respectively, all surpassing endoscopists. Detection rates for mild, moderate, and severe CAG were 93%, 95%, and 99%, respectively. These findings demonstrate high diagnostic accuracy of AI-based models in CAG detection, with robust performance across varying severity levels, suggesting broad applicability in clinical practice.

Beyond CAG diagnosis, AI has been applied to differentiate EGC from gastritis—a common diagnostic dilemma. Horiuchi et al.[81] used a CNN system with ME-NBI endoscopy to distinguish EGC from gastritis. On a test set of 151 EGC and 107 gastritis images, the model achieved 95.4% sensitivity, 71.0% specificity, 82.3% PPV, and 91.7% NPV; furthermore, it demonstrated a processing speed of 51.8 images per second (0.02 s per image), enabling rapid and accurate differentiation. These studies collectively underscore AI's potential to enhance detection of gastric precancerous conditions and reduce diagnostic uncertainty.

AI-assisted risk stratification: *Helicobacter pylori* infection

Helicobacter pylori infection constitutes a significant risk factor for gastric cancer[82,83]; different infection statuses correspond to different sites of early-stage gastric cancer, with its endoscopic identification being highly dependent on the examiners' experience, thereby contributing to inter-observer variability[77]. During routine endoscopy, *H. pylori* infection can be recognized based on the morphological features of the gastric mucosa. Previous studies have reported that gastric mucosal edema, diffuse erythema, coarse folds, or a nodular appearance characterize *H. pylori*-positive gastritis, whereas negative mucosa typically exhibits regularly arranged small veins and basal gland polyps[84,85].

Shichijo et al.[86] employed a 22-layer CNN model to train and validate using *H. pylori*-positive and -negative endoscopic images. The CNN model trained using anatomical region classification demonstrated significantly higher diagnostic accuracy than the average of 23 endoscopists (5.3% higher, 95% CI 0.3–10.2), comparable to six certified specialists. Moreover, the model required only 194 s of processing time (vs 230 min for manual assessment), thereby markedly highlighting its efficiency advantage (the discrepancy may stem from differences between batch processing and case-by-case review). Subsequently, the research team incorporated post-eradication endoscopic images for further validation. Diagnostic accuracy for *H. pylori*-negative images reached 80%, rising to 84% post-eradication, while positive images achieved 48% accuracy—a figure comparable to that of experienced endoscopists. This indicates the system can stratify *H. pylori* infection risk during endoscopy without prior knowledge of infection status, thereby reducing practitioner workload[87].

Other CNN-based systems have confirmed these findings. Itoh et al.[88] reported a diagnostic sensitivity and specificity of 86.7% each, with an AUC of 0.956, for *H. pylori* detection. Nakashima et al.[89] compared AI performance across different imaging modalities in a prospective study. With WLI, the AI achieved an AUC of 0.66 for *H. pylori* diagnosis, whereas under BLI and linked color imaging, the AUC reached 0.96 and 0.95, respectively. These results demonstrate that AI retains robust predictive efficacy when applied to enhanced endoscopic techniques, offering a scalable solution for improving diagnostic consistency in *H. pylori* infection. Nevertheless, most gastric AI models were trained on expert-annotated images; in routine endoscopy, performance may be affected by mucus, food residue, inadequate insufflation, small flat lesions, and gastritis-like background.

AI and early colorectal cancer

The latest data released by the International Agency for Research on Cancer (IARC) indicates that colorectal cancer (CRC) ranks as the third most commonly diagnosed cancer globally and the second leading cause of cancer-related mortality[90]. In the latest annual cancer report published by China's National Cancer Center, CRC ranked as the second most commonly diagnosed cancer and the fourth leading cause of cancer death in China during 2022[91]. Overall, both nationally and globally, CRC incidence and mortality rates consistently feature among the top five[92,93].

CRC generally develops from colorectal adenomas, ulcerative colitis (UC), and other conditions, with the 'adenoma–adenocarcinoma pathway' being the primary mechanism of carcinogenesis[94,95]. Colorectal adenomas account for 85% to 90% of all colorectal precancerous lesions, and potentially even higher proportions[96,97]. Therefore, the timely detection and excision of colorectal precancerous lesions and early-stage cancers are of paramount importance[98,99]. Colonoscopy remains the gold standard for early screening of CRC[97]. However, studies indicate that colonoscopy is not entirely reliable, as missed lesions still occur[3,100]. This may be

https://doi.org/10.48130/git-0026-0013

associated with factors such as bowel preparation quality, examination duration, operator experience, and other factors[100,101]. Advances in AI technology within this field hold significant potential. This section therefore provides a systematic review of research progress and clinical impact regarding AI's role in assisting the diagnosis of colorectal precancerous lesions and early-stage cancers (Table 4).

Computer-aided detection

Over the past decade, researchers globally have trained and validated CADe diagnostic models with high sensitivity and specificity (both exceeding 90%) using retrospective colonoscopy images from diverse ethnic groups and hospitals[102,103]. In the past 5 years, several studies have been conducted to compare outcomes between colonoscopies using CADe systems and those following standard colonoscopy protocols. Multiple RCTs yielded highly consistent findings: studies by Wang et al.[104], Glissen et al.[105], and Kamba et al.[106] all confirm that AI-assisted colonoscopy achieves significant increases in adenoma detection rate (ADR) and polyp detection rate (PDR), alongside significant reductions in AMR and polyp miss rate (PMR)[107].

Building upon this core consensus, research has begun to expand into practical implementation details. Repici et al. investigated the effect of AI-assisted systems on colonoscopy procedures, finding no statistically significant difference in withdrawal time between the two groups[108]. This result aligns with the findings of Lee et al.[109], indicating that clinical use of CADe systems does not increase false-positive rates, thus avoiding additional examination time while delivering secondary benefits of improved examination quality and consistency[110]. Furthermore, CADe systems demonstrated higher detection rates for ≤ 5 mm polyps compared to standard colonoscopy groups. This finding aligns with established literature[111,112] that smaller polyps are more likely to be missed within the field of view than larger ones, highlighting the system's advantage in detecting minipolyps. Although minipolyps carry a lower malignant potential, the overall increase in PDR contributes to reducing the risk of CRC development. Concurrently, validation studies in special populations are ongoing.

Given that UC increases the risk of CRC, Maeda et al. developed an AI-assisted system that identified intestinal mucosal lesions, achieving an accuracy rate up to 91% and enabling timely recognition and intervention[113]. These findings suggest that CADe systems hold promise for the fully automated identification of persistent inflammation associated with ulcerative lesions. High-quality evidence, particularly from RCTs, has established CADe as an effective tool for enhancing the detection efficacy of colonoscopy. Consequently, the research focus has shifted rapidly from CADe to the subsequent stage of greater clinical decision-making value: CADx.

Computer-aided diagnosis

Building upon its detection capabilities, AI is now evolving towards 'accurate recognition'. CADx technology offers histopathological predictions for colorectal polyps (tumorous or non-tumorous), thereby significantly aiding endoscopists' optical diagnosis. Currently, CADx technology typically relies on electronically stained endoscopic images, such as those produced by NBI. Colon polyp classification algorithms can identify and categorize colorectal polyps from medical images and videos. Early classification methods involved manually defining specific tissue characteristics, a process that proved both time-consuming and cumbersome for clinicians, yet failed to guarantee classification accuracy. Consequently, current research predominantly employs CNNs for colon polyp classification, enabling models to achieve higher classification accuracy and faster processing times.

Jin et al.[114] proposed a CNN model for colorectal polyp classification capable of distinguishing small-sized adenomatous and hyperplastic polyps. They employed a private dataset comprising 2,450 polyp images for training and testing, achieving an 86.7% classification accuracy. The primary contribution of this study is the pioneering comparison of CNN models with physicians using the identical test set, as well as the evaluation of whether physician accuracy improves with AI-assisted diagnosis. These findings provide stronger evidence for the viability of AI-assisted diagnosis. However, a limitation is the exclusion of sessile serrated lesions (SSL) from the training set. Since the model only classifies adenomatous and hyperplastic polyps, it fails to meet clinical requirements fully. To

Table 4. Application of AI in early colorectal cancer.

Ref.	Country	Study type	Subjects	Model/ algorithm	Endoscope type	Sample size	Sensitivity (%)	Specificity (%)	Accuracy (%)	AUC
Maeda et al. (2019)[113]	Japan	Retrospective, single-center	UC	CAD	EC/NBI	Training set: 12,900 Validation set: 9,935	74.0	97.0	91.0	NR
Jin et al. (2020)[114]	Korea	Retrospective, single-center	Colon polyps	CNN	NBI	Training set: 2,150 Test set: 300	83.3	91.7	86.7	NR
Zachariah et al. (2020)[115]	USA	Retrospective, multicenter (2)	Colon polyps	CNN	WLI/NBI	Training set: 4,222 Validation set: 1,055/634	NBI + WLI: 96.0 WLI: 95.0 NBI: 96.0	NBI + WLI: 90.0 WLI: 88.0 NBI: 90.0	NBI + WLI: 94.0 WLI: 92.0 NBI: 94.0	NR
Patino-Barrientos et al. (2020)[116]	USA	Retrospective, multicenter (2)	Colon polyps	DCNN	NR	Training set: 6,457 Validation set: 1,519	86.0	NR	83.0	NR
Liu et al. (2022)[117]	China	Retrospective, single-center	Colon polyps	Polyp-DedNet (CNN)	WLI/NBI	Training set: 6,823 Test set: 426	NR	NR	Four-class classification: 89.91 Six-class classification: 85.13	0.906–0.996
Rahman et al. (2021)[118]	Bangladesh	Retrospective, single-center	Colon polyps	CNN	WLI/NBI	Training set: 26,512 Test set: not specified	96.17	98.97	98.53	0.9912

UC: ulcerative colitis. CNN: convolutional neural networks. DCNN: deep convolutional neural network. CAD: computer-assisted detection. EC: endocytoscopy. NBI: narrow-band imaging. WLI: white-light imaging. AUC: area under the curve. NR: not reported. The original study did not explicitly state this information.
'Validation set' indicates that the original study utilized a validation cohort but did not explicitly define it as internal (e.g., data split) or external (e.g., independent institution). The values in parentheses indicate the specific data of each center.

address this limitation, Zachariah et al.[115] designed a model for classifying small adenomatous and serrated polyps (hyperplastic polyps and SSL). They employed 5,278 images (including WLI and NBI) for training and testing. Experimental results demonstrated that the model achieved an overall accuracy of 94% in distinguishing adenomatous and serrated polyps, with accuracies of 92% for WLI and 94% for NBI. This discrepancy may be attributed to the fact that optical diagnoses via WLI typically provide less information than NBI examinations.

Patino-Barrientos et al.[116] proposed a model for classifying colonic polyps as benign or malignant. The results demonstrated that DL models can be effectively employed for early cancer diagnosis, achieving a classification accuracy of 83%. Limitations of this study include relatively slow classification speeds, which fall short of meeting real-time diagnostic requirements, and insufficient classification accuracy for similar polyps due to limited dataset availability. While the aforementioned research focused on binary classification, basic binary classification models cannot fully satisfy clinical needs in practical applications. Consequently, as the field advances, there is a growing emergence of complex multi-class classification models. Liu et al.[117] proposed a CNN named Polyp-DedNet for four-class and six-class colorectal polyps classification tasks. They categorized polyps into four classes based on the polyp classification criteria established by the World Health Organization (WHO) and the Workgroup Serrated Polyps and Polyposis (WASP): conventional adenoma, hyperplastic polyps, SSA/P, and normal. Conventional adenomas were further subdivided into tubular adenoma, villous adenoma, and villous-tubular adenoma. Results demonstrated that the proposed Polyp-DedNet achieved average accuracy rates of 89.91% and 85.13% for four-class and six-class colorectal polyp classification, respectively. In the field of colorectal polyp classification, researchers have increasingly adopted ensemble approaches combining multiple CNN models to enhance classification accuracy. Rahman et al.[118] proposed a stacked ensemble approach to enhance polyp classification performance. The proposed model achieved 98.53% classification accuracy for hyperplastic, serrated, adenomatous polyps, and non-polyps. Results demonstrated superiority over single networks, with the ensemble model not only compensating for individual model limitations while improving overall performance but also enabling near real-time polyp classification. That said, most CADx models have been validated on high-quality NBI images; in real-world WLI-only settings, small polyps, sessile serrated lesions, inflammation, and blood or mucus coverage may reduce classification accuracy.

CADx holds considerable promise in assisting endoscopists with optical diagnosis. However, successful implementation requires seamless integration of CADx tools into endoscopic workflows without requiring image enhancement or magnification. In the future, CADx technology is poised to enable the diagnosis of lesions under high-definition WLI endoscopy. Integrating CADe with CADx and combining AI-assisted endoscopy with AI-powered pathology may offer more effective approaches for diagnosing and managing colorectal precancerous lesions and early-stage cancers.

Ensuring early cancer detection: AI-assisted monitoring of digestive endoscopy quality

High-quality bowel preparation and blind-spot monitoring are critical to reducing the miss rate of early cancers; therefore, AI-based quality control is an indispensable component of the early cancer screening system. AI performs real-time identification and accurate classification of endoscopic images[16], enabling it to serve as a 'third eye' for continuous monitoring of endoscopic examination quality[17]. This establishes it as an objective evaluation metric for quality control and procedure standardization. Mucosal visualization constitutes the fundamental prerequisite for identifying lesions during endoscopy. The application of AI to evaluate and enhance the quality of gastrointestinal mucosal exposure represents one direction for AI development and represents a pivotal advancement in endoscopic examination quality[119].

One of the key quality indicators in colonoscopy is the adequacy of bowel preparation. Zhou et al.[120] demonstrated that AI achieved an accuracy rate of 99.33% in assessing bowel preparation, outperforming endoscopists. This indicates that AI-based bowel preparation assessment systems can be robustly applied in clinical practice.

In upper gastrointestinal endoscopy, complete visualization of all anatomical sites is essential for thorough examination. Accurate site identification underpins AI-based assessment of examination completeness. In a single-center study, Takiyama et al.[16] categorized static WLI endoscopic images of the upper gastrointestinal tract into seven anatomical regions (larynx, esophagus, upper/middle/lower stomach, duodenum), achieving an overall accuracy of 97%. The system demonstrated robustness even when trained on low-quality images, highlighting its potential for real-time anatomical monitoring. Expanding on this approach, Wu et al.[66] developed EndoAngel, an AI system that monitors blind spots during gastroscopy in real time. In a multicenter RCT, EndoAngel significantly reduced the number of blind spots (from 9.82 to 5.38 per procedure) and increased inspection time, demonstrating that AI can effectively enhance examination completeness.

In colonoscopy, the cecal insertion rate (CIR) and withdrawal time are two key quality indicators that directly influence ADR and the risk of interval cancer[121–123]. Achieving a CIR ≥ 95% is recommended as a benchmark for screening colonoscopy by the American Gastroenterological Association (AGA)[124], and a withdrawal time of at least 6 min is widely accepted as a quality standard by the European Society of Gastrointestinal Endoscopy and AGA[123,125]. Previously, the manual recording of these metrics was both time-consuming and labor-intensive, and prone to bias. Today, computer-assisted quality (CAQ) systems can automatically identify the cecum by analyzing anatomical landmarks in endoscopic images, thereby calculating CIR and withdrawal time in real time without disrupting clinical workflows. Zhu et al.[126] developed a computer vision-based system that accurately identified the cecum with a 95.80% accuracy rate and correctly recorded the start and end times of colonoscopies. In addition to total withdrawal time, Lui et al.[127] proposed a novel quality metric termed 'effective withdrawal time', which was found to be a superior predictor of ADR compared to total withdrawal time.

Examination duration is an established quality metric for endoscopy. Kawamura et al.[128] analyzed 55,786 gastroscopy procedures and found that examination time ≥ 7 min was associated with significantly higher lesion detection rates compared to shorter examinations. Based on this, the European Society of Gastrointestinal Endoscopy recommends a minimum gastroscopy duration of 7 min[129]. AI systems can monitor procedure time in real time, alerting endoscopists when duration falls below recommended thresholds, thereby promoting adherence to quality standards and potentially reducing miss rates.

In summary, AI is emerging as a powerful tool for monitoring and improving endoscopic quality across multiple dimensions—bowel

https://doi.org/10.48130/git-0026-0013

preparation adequacy, cecal intubation rate, withdrawal time, examination duration, anatomical site coverage, and reduction of blind spots. By providing real-time, objective feedback, AI systems hold promise to standardize endoscopic practice, reduce operator-dependent variability, and ultimately improve detection rates of early gastrointestinal neoplasia.

AI applications in clinical prediction of early gastrointestinal cancer

AI is increasingly utilized for clinical prediction in gastrointestinal oncology[130]. Its primary benefit resides in enhancing the accuracy and efficiency of early diagnosis through multidimensional data analysis. AI can integrate endoscopic images, pathology, genomics, and clinical data to develop individualized early cancer risk models. These models fulfill two critical functions: stratifying high-risk populations for targeted screening and guiding personalized post-treatment surveillance strategies. The following subsections address these two functions in turn.

Stratifying high-risk populations for targeted screening

AI-based prediction models have shown potential for identifying individuals at elevated risk for neoplastic progression. In early EC, Ikenoyama et al.[41] developed an AI system that detected multiple Lugol-voiding lesions in WLI and NBI images, helping identify patients at high risk for ESCC without requiring chromoendoscopy. Such approaches enable non-invasive risk stratification and may facilitate earlier intervention in high-risk cohorts.

In the context of gastric cancer, Horiuchi et al.[81] demonstrated the ability of a convolutional neural network to differentiate gastric cancer from gastritis using magnified endoscopy with narrow-band imaging, thereby supporting the identification of high-risk individuals who may benefit most from targeted screening and early intervention.

By directing surveillance toward those most likely to benefit, these models help optimize the allocation of endoscopic resources and support targeted screening programs.

Guiding personalized post-treatment surveillance

In the context of post-treatment monitoring, prediction models have addressed both pre-cancerous conditions and post-treatment outcomes[131]. In gastric cancer, Gupta et al.[132] demonstrated that ML algorithms incorporating histopathological parameters could predict 5-year disease-free survival in gastric cancer patients, with the random forest model achieving an accuracy of 84%, outperforming conventional TNM staging. Prediction modeling in CRC has advanced rapidly in this regard. Levin et al.[133] developed a multivariable prediction model for CRC risk in patients awaiting surveillance colonoscopy after polypectomy. Using data from over 50,000 patients, the model achieved an AUC of 0.73 on internal validation, significantly outperforming a guideline-based model (AUC 0.52). Although performance declined on external validation, periodic model updates reinstated predictive accuracy, highlighting the importance of continuous refinement. More recently, Shi et al.[134] constructed the first ML model to predict colorectal polyp recurrence 1 year after endoscopic mucosal resection. Among five algorithms tested, XGBoost exhibited superior performance, with AUCs of 0.909, 0.921, and 0.963 in training, internal validation, and prospective validation sets, respectively. This model facilitates the rapid assessment of individual recurrence risk, supporting personalized follow-up strategies.

Challenges and future prospects

Challenges

The integration of AI with existing diagnostic and treatment processes is dramatically transforming the current medical landscape. It is shifting from an 'experience-driven' approach to a 'data-intelligent collaboration' model (Fig. 2). This integration aims to deeply engage with clinical pathways through a three-tiered integration model of 'substitution–enhancement–collaboration'. Before diagnosis, intelligent preconsultation systems, such as Ping An Good Doctor's AI triage, can shorten patient waiting times by up to 40%[135]. During diagnosis, real-time AI marking in endoscopy, for example, Japan's AI-SCOPE, achieves a sensitivity of 92.70% in detecting EGC. Meanwhile, IBM Watson Oncology provides evidence-based support for tumor treatment planning[136,137]. After diagnosis, AI-driven chronic disease management platforms, like Omada Health, utilize data from wearable devices to provide dynamic risk warnings for complications (Fig. 3)[138].

As highlighted above, the caveats for esophageal, gastric, and colorectal cancer AI are not organ-specific but share common themes: most models were developed and validated retrospectively using curated, high-quality datasets from expert centers. External validation remains limited, and real-world performance may be degraded by variations in image quality, endoscopic devices, operator experience, and patient populations. These commonalities indicate a systemic gap between research performance and clinical effectiveness. Therefore, AI is not a panacea; its clinical implementation depends on cooperation among technology developers, clinicians, policymakers, and patients. The integration process faces severe challenges. These include a lack of model generalization caused by data silos—for example, IBM Watson Health withdrew from the market because it failed to adapt to localized data. Additional challenges include the conflict between traditional linear workflows and AI parallel processing, as well as a trust crisis among doctors and patients regarding 'black box decisions'. In response, federated learning and explainable AI technologies (e.g., the LIME algorithm for visualizing diagnostic rationale) have become essential in overcoming these barriers. Federated learning enables collaborative model training across institutions without sharing raw patient data, thereby mitigating data-silo-induced generalization failure and addressing privacy concerns in multicenter deployment. Meanwhile, explainable AI—such as the LIME algorithm for visualizing diagnostic rationale—alleviates the 'black-box' trust crisis among clinicians and patients by making model decisions interpretable and auditable.

Furthermore, the rapid development of AI also faces additional challenges. These include: (1) the lack of prospective RCT evidence; (2) the ethical issues in medical applications; (3) limitations in primary hospitals; (4) the quality of test images in AI-assisted systems; and (5) the public perception of AI's impact in the medical field. First, there is a notable scarcity of evidence from prospective RCTs, given that most existing studies are retrospective single-arm trials. Furthermore, there is significant heterogeneity in the reporting of validation strategies; many studies fail to explicitly delineate whether the validation cohort was derived from an internal data split or an independent external institution. Considering the

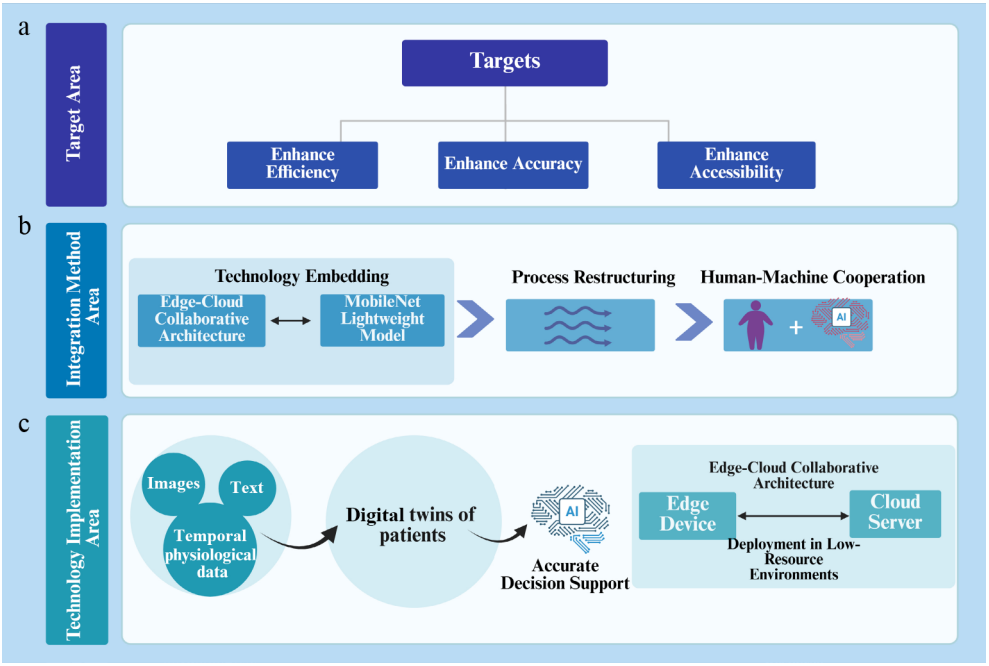

Fig. 2 AI transforms medical patterns from experience-driven to data-intelligent collaboration. (a) Target area: establish three optimization goals of medical AI—efficiency, accuracy, and service accessibility. (b) Integration method area: three technical paths—model embedding, process restructuring, and human-machine cooperation. (c) Technology implementation area: underlying technologies—multimodal data, patient digital twins, and edge-cloud deployment. Created with BioRender.com.

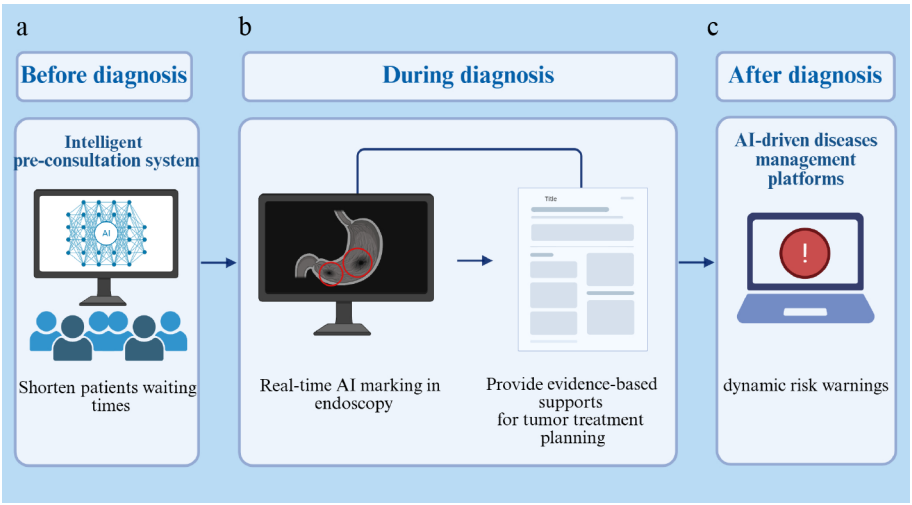

Fig. 3 AI and reengineering of the diagnostic and treatment processes. (a) Before diagnosis: intelligent pre-consultation system to reduce patients' waiting time. (b) During diagnosis: real-time AI lesion marking in endoscopy, offering evidence support for tumor treatment planning. (c) After diagnosis: AI-driven disease management platform for dynamic patient risk warnings. Created with BioRender.com.

anticipated integration of AI technology into real-time endoscopic examinations, future studies must strictly adhere to standardized reporting guidelines and prioritize prospective, externally validated investigations, which are essential for verifying clinical robustness. Second, ethical issues surrounding the medical applications of AI include ambiguous legal liability for AI misdiagnosis, alongside an ongoing debate regarding whether doctors or algorithm developers should assume this responsibility. Third, primary hospitals face challenges due to insufficient resources and infrastructure, which restrict their ability to develop or implement AI technology. Only teaching or affiliated hospitals with expert pathologists and endoscopists can use relevant technology to assist in early cancer screening of the digestive tract. Fourth, the test images used in existing AI-assisted systems are of excellent quality, as they have been carefully selected and validated by physicians. However, in real-world endoscopic procedures, image quality may be compromised due to insufficient preparation of the digestive tract, poor lighting, and unfavorable angles. Consequently, the images may not meet the minimum recognizable thresholds required by AI-assisted systems. Fifth, a survey study showed that only 16.68% of the general population believes that AI has a significant impact in the medical field, whereas the highest proportion, 71.44%, perceived only a slight impact[72]. This indicates that although AI has started to gain initial traction in the medical field, its scope of application remains limited.

Beyond technical performance, the clinical translation of AI endoscopy systems is critically dependent on regulatory approval

https://doi.org/10.48130/git-0026-0013

and rigorous validation. Several computer-aided detection and diagnosis systems for gastrointestinal endoscopy have already entered clinical practice following regulatory clearance. For example, GI Genius (Medtronic) was the first AI-assisted colonoscopy device to receive FDA clearance (*de novo* classification in 2021) and CE marking in Europe[139]. However, approval pathways and evidence requirements vary considerably across jurisdictions[140], and a notable gap persists between the volume of regulatory authorizations and the availability of post-deployment real-world evidence; approved algorithms may exhibit substantially higher false-positive burdens in unselected clinical cases than in the curated validation datasets used for approval[141]. Moreover, prospective, multicenter validation under real-world conditions—including poor bowel preparation, motion artifacts, and non-standard imaging—remains essential to establish generalizable performance and justify widespread clinical adoption[142]. Future research should therefore align technological development with evolving regulatory expectations and standardized clinical-validation frameworks.

Future prospects

One important role of medical AI applications is their significant potential to empower primary healthcare institutions and primary care physicians. They are particularly effective in addressing issues such as the uneven distribution of qualified medical resources, insufficient practitioner experience, and low service efficiency[143]. By integrating risk stratification (such as *H. pylori* status and gastric atrophy), real-time lesion detection, and intra-procedural quality monitoring, AI systems can act as a comprehensive 'virtual preceptor' for primary care physicians. Additionally, when AI is combined with 5G technology, it enables real-time remote consultations, alleviating the shortage of endoscopists in primary hospitals and playing a pivotal role in empowering primary healthcare[144]. Finally, AI can serve as a standardized training tool by providing a simulated lesion library that shortens practitioners' learning curve.

Overall, while the application of AI in clinical settings remains at an early stage, widespread adoption will likely necessitate a significant timeframe[99]. However, as AI technologies—particularly those based on DL—continue to advance, the integration of AI into precancerous lesion screening, early cancer diagnosis, quality control, and prognostic prediction holds promise to deliver enhanced diagnostic efficiency and accuracy. Beyond the endoscopic applications addressed in this review, AI-driven analysis of histopathological images represents a promising frontier for further refining individualized risk stratification and prognostic prediction, a direction that merits dedicated exploration in future work. Consequently, AI has the potential to accelerate progress in gastrointestinal oncology and the broader medical field, thereby benefiting more patients. Definitive conclusions regarding its impact on patient outcomes must await the completion of robust, prospective randomized controlled trials.

Conclusions

AI is reshaping the landscape of early diagnosis and treatment of gastrointestinal tumors. The studies on esophageal, gastric, and colorectal cancer systematically reviewed herein collectively demonstrate that DL algorithms have achieved diagnostic performance comparable to that of experts in lesion detection, characterization, assessment of invasion depth and resection margins, and risk stratification, while significantly enhancing the sensitivity of non-expert endoscopists; moreover, these algorithms exhibit greater clinical utility within multimodal systems integrating WLI, NBI, iodine staining, and ME, as well as in combined CADe/CADx approaches, holding promise to shift early tumor management from an experience-driven to a data-intelligent paradigm. It must be acknowledged, however, that the vast majority of performance metrics reported to date were derived from retrospectively collected, expert-annotated datasets obtained under optimized imaging conditions, and therefore serve to demonstrate technical feasibility rather than to establish real-world effectiveness. Limited external validation, together with performance degradation arising from heterogeneity in image quality, endoscopic devices, operator experience, and patient populations, constitutes a common systemic limitation across the esophageal, gastric, and colorectal domains. Consequently, only through large-scale prospective randomized controlled trials to validate clinical efficacy, advancement of multicenter, cross-device, and cross-population algorithm generalizability, exploration of multimodal synergy linking endoscopic and pathological AI, and concurrent refinement of institutional support encompassing data standardization, regulatory approval, and accountability frameworks, can AI truly become a reliable adjunct for endoscopists and meaningfully improve the prognosis of patients with early gastrointestinal tumors.

Ethical Statements

Not applicable.

Author contributions

The authors confirm their contributions to the paper as follows: conceptualization, methodology, writing – original draft: Yang X; supervision, writing – review and editing: Cui M, Sun C, Fan Q; writing – review and editing: Li Q; writing – review and editing, supervision, funding acquisition: Zhang M. All authors reviewed the results and approved the final version of the manuscript.

Data availability

Data sharing is not applicable to this article, as no datasets were generated or analyzed during the current study.

Acknowledgments

In this study, we are grateful to Prof. Mingxin Zhang for his guidance in the direction of the research. This study would not have been possible without the support of the Digestive New Youth Research Group. We thank Prof. Chao Sun and Qingling Fan for assistance with proofreading and image editing. Additionally, we would like to extend our gratitude to all members of our research group for their valuable contributions, insightful discussions, and unwavering support throughout the entire project. We thank Yiteng Kaisi for the figures exported with BioRender. Finally, I would like to thank myself for being self-disciplined and never giving up, always full of sincerity and courage to achieve my goals. This study was supported by the Xi'an Science and Technology Program Project (25YXYJYB00130), the Special Service Project of Shaanxi Provincial Department of Education (24JC079), the Supporting Fund Project of the First Affiliated Hospital of Xi'an Medical University (XYYFYPT2026-06, 2024JYKY01), and the Xi'an Weiyang District Project (202412).

Conflict of interest

The authors declare that they have no conflict of interest.

Dates

Received 5 August 2026; Revised 21 October 2026; Accepted 3 November 2026; Published online 25 November 2026

References

[1] Sung H, Ferlay J, Siegel RL, Laversanne M, Soerjomataram I, et al. 2021. Global cancer statistics 2020: GLOBOCAN estimates of incidence and mortality worldwide for 36 cancers in 185 countries. *CA: A Cancer Journal for Clinicians* 71(3):209–249

[2] Hu T, Wang S, Wang Y, Wang X, Shang L, et al. 2025. Burden of digestive system malignancies and its impact on life expectancy in China, 2004–2021. *eGastroenterology* 3(2):e100148

[3] Jiang W, Xin L, Zhu S, Liu Z, Wu J, et al. 2023. Risk factors related to polyp miss rate of short-term repeated colonoscopy. *Digestive Diseases and Sciences* 68(5):2040–2049

[4] Digestive Endoscopy Special Committee of Endoscopic Physicians Branch of Chinese Medical Association, Cancer Endoscopy Committee of China Anti-Cancer Association. 2019. 中国消化内镜诊疗相关肠道准备指南 (2019, 上海) [Chinese guideline for bowel preparation for colonoscopy (2019, Shanghai)]. *中华内科杂志 [Chin J Intern Med]* 58(7):485–495 (in Chinese)

[5] Menon S, Trudgill N. 2014. How commonly is upper gastrointestinal cancer missed at endoscopy? A meta-analysis. *Endoscopy International Open* 2(2):E46–E50

[6] Tischendorf JJ, Gross S, Winograd R, Hecker H, Auer R, et al. 2010. Computer-aided classification of colorectal polyps based on vascular patterns: a pilot study. *Endoscopy* 42(3):203–207

[7] Kominami Y, Yoshida S, Tanaka S, Sanomura Y, Hirakawa T, et al. 2016. Computer-aided diagnosis of colorectal polyp histology by using a real-time image recognition system and narrow-band imaging magnifying colonoscopy. *Gastrointestinal Endoscopy* 83 (3):643–649

[8] Hadley TD, Pettit RW, Malik T, Khoei AA, Salihu HM. 2020. Artificial intelligence in global health-a framework and strategy for adoption and sustainability. *International Journal of MCH and AIDS* 9(1):121–127

[9] Sarker IH. 2021. Machine learning: algorithms, real-world applications and research directions. *SN Computer Science* 2(3):160

[10] LeCun Y, Bengio Y, Hinton G. 2015. Deep learning. *Nature* 521(7553):436–444

[11] Radhakrishnan A, Beaglehole D, Pandit P, Belkin M. 2024. Mechanism for feature learning in neural networks and backpropagation-free machine learning models. *Science* 383(6690):1461–1467

[12] Chartrand G, Cheng PM, Vorontsov E, Drozdzal M, Turcotte S, et al. 2017. Deep learning: a primer for radiologists. *RadioGraphics* 37(7):2113–2131

[13] Min JK, Kwak MS, Cha JM. 2019. Overview of deep learning in gastrointestinal endoscopy. *Gut and Liver* 13(4):388–393

[14] Choi J, Shin K, Jung J, Bae HJ, Kim DH, et al. 2020. Convolutional neural network technology in endoscopic imaging: artificial intelligence for endoscopy. *Clinical Endoscopy* 53(2):117–126

[15] Mori Y, Kudo SE, Mohmed HEN, Misawa M, Ogata N, et al. 2019. Artificial intelligence and upper gastrointestinal endoscopy: current status and future perspective. *Digestive Endoscopy* 31(4):378–388

[16] Takiyama H, Ozawa T, Ishihara S, Fujishiro M, Shichijo S, et al. 2018. Automatic anatomical classification of esophagogastroduodenoscopy images using deep convolutional neural networks. *Scientific Reports* 8(1):7497

[17] Wang Z, Zhao S, Bai Y. 2018. Artificial intelligence as a third eye in lesion detection by endoscopy. *Clinical Gastroenterology and Hepatology* 16(9):1537

[18] Cao W, Qin K, Liu B, Chen W. 2025. Cancer statistics in China: epidemiology, risk factors, and prevention. *Chinese Journal of Cancer Research* 37(6):912–928

[19] Xin L, Gao Y, Cheng Z, Wang T, Lin H, et al. 2022. Utilization and quality assessment of digestive endoscopy in China: results from 5-year consecutive nationwide surveys. *Chinese Medical Journal* 135(16):2003–2010

[20] He Z, Ke Y. 2025. Evolving diagnostic and surveillance strategies in esophageal cancer screening: evidence from population-based studies in China. *Chinese Journal of Cancer Research* 37(6):929–936

[21] de Arruda Henry MAC, Lerco MM, Ribeiro PW, Rodrigues MAM. 2014. Epidemiological features of esophageal cancer. Squamous cell carcinoma versus adenocarcinoma. *Acta Cirurgica Brasileira* 29(6):389–393

[22] Oh TK, Kim K, Jheon SH, Do SH, Hwang JW, et al. 2018. Long-term oncologic outcomes, opioid use, and complications after esophageal cancer surgery. *Journal of Clinical Medicine* 7(2):33

[23] Yan P, Yuan X, Zhang Q, Hu B. 2022. 人工智能在浅表食管鳞状细胞癌及癌前病变内镜诊断中的应用进展 [Progress of artificial intelligence in endoscopic diagnosis of superficial esophageal squamous carcinoma and precancerous lesions]. *中国胸心血管外科临床杂志 [Chin J Clin Thorac Cardiovasc Surg]* 29(11):1217–1222 (in Chinese)

[24] Cai SL, Li B, Tan WM, Niu XJ, Yu HH, et al. 2019. Using a deep learning system in endoscopy for screening of early esophageal squamous cell carcinoma (with video). *Gastrointestinal Endoscopy* 90(5): 745–753.e2

[25] Tang D, Wang L, Jiang J, Liu Y, Ni M, et al. 2021. A novel deep learning system for diagnosing early esophageal squamous cell carcinoma: a multicenter diagnostic study. *Clinical and Translational Gastroenterology* 12(8):e00393

[26] Li B, Cai SL, Tan WM, Li JC, Yalikong A, et al. 2021. Comparative study on artificial intelligence systems for detecting early esophageal squamous cell carcinoma between narrow-band and white-light imaging. *World Journal of Gastroenterology* 27(3):281–293

[27] Horie Y, Yoshio T, Aoyama K, Yoshimizu S, Horiuchi Y, et al. 2019. Diagnostic outcomes of esophageal cancer by artificial intelligence using convolutional neural networks. *Gastrointestinal Endoscopy* 89(1):25–32

[28] Yuan XL, Guo LJ, Liu W, Zeng XH, Mou Y, et al. 2022. Artificial intelligence for detecting superficial esophageal squamous cell carcinoma under multiple endoscopic imaging modalities: a multicenter study. *Journal of Gastroenterology and Hepatology* 37(1):169–178

[29] Ishihara R, Arima M, Iizuka T, Oyama T, Katada C, et al. 2020. Endoscopic submucosal dissection/endoscopic mucosal resection guidelines for esophageal cancer. *Digestive Endoscopy* 32(4):452–493

[30] Oyama T, Inoue H, Arima M, Momma K, Omori T, et al. 2017. Prediction of the invasion depth of superficial squamous cell carcinoma based on microvessel morphology: magnifying endoscopic classification of the Japan Esophageal Society. *Esophagus* 14(2):105–112

[31] Mizumoto T, Hiyama T, Quach DT, Sanomura Y, Urabe Y, et al. 2018. Magnifying endoscopy with narrow band imaging in estimating the invasion depth of superficial esophageal squamous cell carcinomas. *Digestion* 98(4):249–256

[32] Tokai Y, Yoshio T, Aoyama K, Horie Y, Yoshimizu S, et al. 2020. Application of artificial intelligence using convolutional neural networks in determining the invasion depth of esophageal squamous cell carcinoma. *Esophagus* 17(3):250–256

[33] Nakagawa K, Ishihara R, Aoyama K, Ohmori M, Nakahira H, et al. 2019. Classification for invasion depth of esophageal squamous cell carcinoma using a deep neural network compared with experienced endoscopists. *Gastrointestinal Endoscopy* 90(3):407–414

[34] Shimamoto Y, Ishihara R, Kato Y, Shoji A, Inoue T, et al. 2020. Real-time assessment of video images for esophageal squamous cell carcinoma invasion depth using artificial intelligence. *Journal of Gastroenterology* 55(11):1037–1045

[35] Kitagawa Y, Uno T, Oyama T, Kato K, Kato H, et al. 2019. Esophageal cancer practice guidelines 2017 edited by the Japan Esophageal Society: part 1. *Esophagus* 16(1):1–24

[36] Ono S, Fujishiro M, Niimi K, Goto O, Kodashima S, et al. 2009. Long-term outcomes of endoscopic submucosal dissection for superficial esophageal squamous cell neoplasms. *Gastrointestinal Endoscopy* 70(5):860–866

[37] Zeki SS, Bergman JJ, Dunn JM. 2018. Endoscopic management of dysplasia and early oesophageal cancer. *Best Practice & Research Clinical Gastroenterology* 36:27–36

[38] Yang C, Chen YH, Hong L, Zheng J, Chen Y, et al. 2021. 联合内镜诊断模型在早期食管癌诊断中的应用价值探讨 [The value of combined endoscopy diagnostic model in the diagnosis of early esophageal cancer]. *现代消化及介入诊疗 [Mod & Intervention]* 26(2):192−196 (in Chinese)

[39] Guo L, Xiao X, Wu C, Zeng X, Zhang Y, et al. 2020. Real-time automated diagnosis of precancerous lesions and early esophageal squamous cell carcinoma using a deep learning model (with videos). *Gastrointestinal Endoscopy* 91(1):41−51

[40] Liu W, Yuan X, Guo L, Pan F, Wu C, et al. 2022. Artificial intelligence for detecting and delineating margins of early ESCC under WLI endoscopy. *Clinical and Translational Gastroenterology* 13(1):e00433

[41] Ikenoyama Y, Yoshio T, Tokura J, Naito S, Namikawa K, et al. 2021. Artificial intelligence diagnostic system predicts multiple Lugol-voiding lesions in the esophagus and patients at high risk for esophageal squamous cell carcinoma. *Endoscopy* 53(11):1105−1113

[42] Thrift AP. 2018. Barrett's esophagus and esophageal adenocarcinoma: how common are they really? *Digestive Diseases and Sciences* 63(8):1988−1996

[43] van der Sommen F, Zinger S, Curvers WL, Bisschops R, Pech O, et al. 2016. Computer-aided detection of early neoplastic lesions in Barrett's esophagus. *Endoscopy* 48(7):617−624

[44] Ghatwary N, Zolgharni M, Ye X. 2019. Early esophageal adenocarcinoma detection using deep learning methods. *International Journal of Computer Assisted Radiology and Surgery* 14(4):611−621

[45] de Groof AJ, Struyvenberg MR, van der Putten J, van der Sommen F, Fockens KN, et al. 2020. Deep-learning system detects neoplasia in patients with barrett's esophagus with higher accuracy than endoscopists in a multistep training and validation study with benchmarking. *Gastroenterology* 158(4):915−929.e4

[46] van der Putten J, de Groof J, Struyvenberg M, Boers T, Fockens K, et al. 2020. Multi-stage domain-specific pretraining for improved detection and localization of Barrett's neoplasia: a comprehensive clinically validated study. *Artificial Intelligence in Medicine* 107:101914

[47] Struyvenberg MR, de Groof AJ, van der Putten J, van der Sommen F, Baldaque-Silva F, et al. 2021. A computer-assisted algorithm for narrow-band imaging-based tissue characterization in Barrett's esophagus. *Gastrointestinal Endoscopy* 93(1):89−98

[48] Iwagami H, Ishihara R, Aoyama K, Fukuda H, Shimamoto Y, et al. 2021. Artificial intelligence for the detection of esophageal and esophagogastric junctional adenocarcinoma. *Journal of Gastroenterology and Hepatology* 36(1):131−136

[49] Abdelrahim M, Saiko M, Maeda N, Hossain E, Alkandari A, et al. 2023. Development and validation of artificial neural networks model for detection of Barrett's neoplasia: a multicenter pragmatic nonrandomized trial (with video). *Gastrointestinal Endoscopy* 97(3):422−434

[50] Katai H, Ishikawa T, Akazawa K, Isobe Y, Miyashiro I, et al. 2018. Five-year survival analysis of surgically resected gastric cancer cases in Japan: a retrospective analysis of more than 100,000 patients from the nationwide registry of the Japanese Gastric Cancer Association (2001−2007). *Gastric Cancer* 21(1):144−154

[51] Hashimoto R, Requa J, Dao T, Ninh A, Tran E, et al. 2020. Artificial intelligence using convolutional neural networks for real-time detection of early esophageal neoplasia in Barrett's esophagus (with video). *Gastrointestinal Endoscopy* 91(6):1264−1271.e1

[52] Ebigbo A, Mendel R, Probst A, Manzeneder J, Souza LA Jr, et al. 2019. Computer-aided diagnosis using deep learning in the evaluation of early oesophageal adenocarcinoma. *Gut* 68(7):1143−1145

[53] Saragoni L. 2015. Upgrading the definition of early gastric cancer: better staging means more appropriate treatment. *Cancer Biology & Medicine* 12(4):355−361

[54] Wei J, Bu Z. 2024. Advances in gastric cancer treatment in 2024: key advancements and emerging trends. *Chinese Journal of Cancer Research* 36(6):592−595

[55] Bang CS, Baik GH, Kim JH, Kim JB, Suk KT, et al. 2015. Effect of training in upper endoscopic biopsy. *The Korean Journal of Helicobacter and Upper Gastrointestinal Research* 15(1):33

[56] Muguruma N, Miyamoto H, Okahisa T, Takayama T. 2013. Endoscopic molecular imaging: status and future perspective. *Clinical Endoscopy* 46(6):603−610

[57] Cohen J, Safdi MA, Deal SE, Baron TH, Chak A, et al. 2006. Quality indicators for esophagogastroduodenoscopy. *The American Journal of Gastroenterology* 101(4):886−891

[58] Hosokawa O, Hattori M, Douden K, Hayashi H, Ohta K, et al. 2007. Difference in accuracy between gastroscopy and colonoscopy for detection of cancer. *Hepatogastroenterology* 54(74):442-4

[59] Hosokawa O, Tsuda S, Kidani E, Watanabe K, Tanigawa Y, et al. 1998. Diagnosis of gastric cancer up to three years after negative upper gastrointestinal endoscopy. *Endoscopy* 30(8):669−674

[60] Januszewicz W, Wieszczy P, Bialek A, Karpinska K, Szlak J, et al. 2019. Endoscopist biopsy rate as a quality indicator for outpatient gastroscopy: a multicenter cohort study with validation. *Gastrointestinal Endoscopy* 89(6):1141−1149

[61] Wang Y, Liu Z, Li W, Zhang Y, Pan K. 2025. Gastric cancer in China: epidemiology, risk factors and screening. *Chinese Journal of Cancer Research* 37(6):937−948

[62] Turshudzhyan A, Rezaizadeh H, Tadros M. 2022. Lessons learned: preventable misses and near-misses of endoscopic procedures. *World Journal of Gastrointestinal Endoscopy* 14(5):302−310

[63] Hirasawa T, Aoyama K, Tanimoto T, Ishihara S, Shichijo S, et al. 2018. Application of artificial intelligence using a convolutional neural network for detecting gastric cancer in endoscopic images. *Gastric Cancer* 21(4):653−660

[64] Tang D, Wang L, Ling T, Lv Y, Ni M, et al. 2020. Development and validation of a real-time artificial intelligence-assisted system for detecting early gastric cancer: a multicentre retrospective diagnostic study. *eBioMedicine* 62:103146

[65] Wu L, Zhou W, Wan X, Zhang J, Shen L, et al. 2019. A deep neural network improves endoscopic detection of early gastric cancer without blind spots. *Endoscopy* 51(6):522−531

[66] Wu L, He X, Liu M, Xie H, An P, et al. 2021. Evaluation of the effects of an artificial intelligence system on endoscopy quality and preliminary testing of its performance in detecting early gastric cancer: a randomized controlled trial. *Endoscopy* 53(12):1199−1207

[67] Tang D, Ni M, Zheng C, Ding X, Zhang N, et al. 2022. A deep learning-based model improves diagnosis of early gastric cancer under narrow band imaging endoscopy. *Surgical Endoscopy* 36(10): 7800−7810

[68] Whei KJ, Jane CK, Hyun-Jae L, Kyo-Young P, Sa-Hong K, et al. 2025. Impact of resection margin status on survival in gastric cancer: a retrospective cohort study. *Chinese Journal of Cancer Research* 37(5):821−836

[69] Liu Q, Ding L, Qiu X, Meng F. 2020. Updated evaluation of endoscopic submucosal dissection versus surgery for early gastric cancer: a systematic review and meta-analysis. *International Journal of Surgery* 73:28−41

[70] Choi J, Kim SG, Im JP, Kim JS, Jung HC, et al. 2010. Comparison of endoscopic ultrasonography and conventional endoscopy for prediction of depth of tumor invasion in early gastric cancer. *Endoscopy* 42(9):705−713

[71] Yanai H, Noguchi T, Mizumachi S, Tokiyama H, Nakamura H, et al. 1999. A blind comparison of the effectiveness of endoscopic ultrasonography and endoscopy in staging early gastric cancer. *Gut* 44(3):361−365

[72] Zhu Y, Wang QC, Xu MD, Zhang Z, Cheng J, et al. 2019. Application of convolutional neural network in the diagnosis of the invasion depth of gastric cancer based on conventional endoscopy. *Gastrointestinal Endoscopy* 89(4):806−815.e1

[73] Yoon HJ, Kim S, Kim JH, Keum JS, Oh SI, et al. 2019. A lesion-based convolutional neural network improves endoscopic detection and depth prediction of early gastric cancer. *Journal of Clinical Medicine* 8(9):1310

[74] Nagao S, Tsuji Y, Sakaguchi Y, Takahashi Y, Minatsuki C, et al. 2020. Highly accurate artificial intelligence systems to predict the invasion depth of gastric cancer: efficacy of conventional white-light imaging,

nonmagnifying narrow-band imaging, and indigo-carmine dye contrast imaging. *Gastrointestinal Endoscopy* 92(4):866−873.e1

[75] Bang CS, Lim H, Jeong HM, Hwang SH. 2021. Use of endoscopic images in the prediction of submucosal invasion of gastric neoplasms: automated deep learning model development and usability study. *Journal of Medical Internet Research* 23(4):e25167

[76] Goto A, Kubota N, Nishikawa J, Ogawa R, Hamabe K, et al. 2023. Cooperation between artificial intelligence and endoscopists for diagnosing invasion depth of early gastric cancer. *Gastric Cancer* 26(1):116−122

[77] Sun D, Lei L, Xia C, Li H, Cao M, et al. 2022. Sociodemographic disparities in gastric cancer and the gastric precancerous cascade: a population-based study. *The Lancet Regional Health - Western Pacific* 23:100437

[78] Du Y, Bai Y, Xie P, Fang J, Wang X, et al. 2014. Chronic gastritis in China: a national multi-center survey. *BMC Gastroenterology* 14(1):21

[79] Guimarães P, Keller A, Fehlmann T, Lammert F, Casper M. 2020. Deep-learning based detection of gastric precancerous conditions. *Gut* 69(1):4−6

[80] Zhang Y, Li F, Yuan F, Zhang K, Huo L, et al. 2020. Diagnosing chronic atrophic gastritis by gastroscopy using artificial intelligence. *Digestive and Liver Disease* 52(5):566−572

[81] Horiuchi Y, Aoyama K, Tokai Y, Hirasawa T, Yoshimizu S, et al. 2020. Convolutional neural network for differentiating gastric cancer from gastritis using magnified endoscopy with narrow band imaging. *Digestive Diseases and Sciences* 65(5):1355−1363

[82] Ma G, Zhang R, Liang H. 2023. 幽门螺杆菌与胃癌相关的研究进展 [Research progress of *Helicobacter pylori* infection and gastric cancer]. *中国肿瘤临床 [Chinese Journal of Clinical Oncology]* 50(1):44−48 (in Chinese)

[83] Li A, Zhang Y, Chen K, Quan X, Yin K, et al. 2025. Association between infection of *Helicobacter pylori* and the risk of reflux oesophagitis occurrence or recurrence: a systematic review and meta-analysis. *eGastroenterology* 3(2):e100121

[84] Rupp S, Papaefthymiou A, Chatzimichael E, Polyzos SA, Spreitzer S, et al. 2022. Diagnostic approach to *Helicobacter pylori*-related gastric oncogenesis. *Annals of Gastroenterology* 35(4):333−344

[85] Yang R, Zhang J, Zhan F, Yan C, Lu S, et al. 2024. Artificial intelligence efficiently predicts gastric lesions, *Helicobacter pylori* infection and lymph node metastasis upon endoscopic images. *Chinese Journal of Cancer Research* 36(5):489−502

[86] Shichijo S, Nomura S, Aoyama K, Nishikawa Y, Miura M, et al. 2017. Application of convolutional neural networks in the diagnosis of *Helicobacter pylori* infection based on endoscopic images. *eBioMedicine* 25:106−111

[87] Shichijo S, Endo Y, Aoyama K, Takeuchi Y, Ozawa T, et al. 2019. Application of convolutional neural networks for evaluating *Helicobacter pylori* infection status on the basis of endoscopic images. *Scandinavian Journal of Gastroenterology* 54(2):158−163

[88] Itoh T, Kawahira H, Nakashima H, Yata N. 2018. Deep learning analyzes *Helicobacter pylori* infection by upper gastrointestinal endoscopy images. *Endoscopy International Open* 6(2):E139−E144

[89] Nakashima H, Kawahira H, Kawachi H, Sakaki N. 2018. Artificial intelligence diagnosis of *Helicobacter pylori* infection using blue laser imaging-bright and linked color imaging: a single-center prospective study. *Annals of Gastroenterology* 31(4):462−468

[90] Bray F, Laversanne M, Sung H, Ferlay J, Siegel RL, et al. 2024. Global cancer statistics 2022: GLOBOCAN estimates of incidence and mortality worldwide for 36 cancers in 185 countries. *CA: A Cancer Journal for Clinicians* 74(3):229−263

[91] Han B, Zheng R, Zeng H, Wang S, Sun K, et al. 2024. Cancer incidence and mortality in China, 2022. *Journal of the National Cancer Center* 4(1):47−53

[92] Cao W, Chen HD, Yu YW, Li N, Chen WQ. 2021. Changing profiles of cancer burden worldwide and in China: a secondary analysis of the global cancer statistics 2020. *Chinese Medical Journal* 134(7):783−791

[93] Department of Medical Administration, National Health Commission of the People's Republic of China, Chinese Medical Association Oncology Branch. 2025. National Health Commission guidelines for diagnosis and treatment of colorectal cancer in China (2025 edition, English version). *Chinese Journal of Cancer Research* 37(6):949−961

[94] Chen L, Hu H, Yuan Y, Weng S. 2024. CSCO guidelines for colorectal cancer version 2024: updates and discussions. *Chinese Journal of Cancer Research* 36(3):233−239

[95] Miao H, Wang Z, Chen S, Wang J, Ma H, et al. 2025. Application of machine learning in the discovery of antimicrobial peptides: exploring their potential for ulcerative colitis therapy. *eGastroenterology* 3(4):e100253

[96] Chen J, Shi H, Chen S, Huang R. 2020. 注气与注水肠镜下结直肠息肉的内镜形态与病理关系的比较 [Comparison of endoscopic morphologic characteristics and pathologic types of colorectal polyps between gas and water injection colonoscopies]. *中国肿瘤临床 [Chinese Journal of Clinical Oncology]* 47(5):236−240 (in Chinese)

[97] Chinese Society of Gastroenterology, Cancer Collaboration Group of Chinese Society of Gastroenterology, Chinese Medical Association. 2022. Chinese consensus on prevention of colorectal neoplasia (2021, Shanghai). *Journal of Digestive Diseases* 23(2):58−90

[98] Hong SW, Byeon JS. 2022. Endoscopic diagnosis and treatment of early colorectal cancer. *Intestinal Research* 20(3):281−290

[99] Maeda Y, Ditonno I, Puga-Tejada M, Zammarchi I, Santacroce G, et al. 2024. Artificial intelligence-enabled advanced endoscopic imaging to assess deep healing in inflammatory bowel disease. *eGastroenterology* 2(3):e100090

[100] Dik VK, Moons LM, Siersema PD. 2014. Endoscopic innovations to increase the adenoma detection rate during colonoscopy. *World Journal of Gastroenterology* 20(9):2200−2211

[101] Kaminski MF, Wieszczy P, Rupinski M, Wojciechowska U, Didkowska J, et al. 2017. Increased rate of adenoma detection associates with reduced risk of colorectal cancer and death. *Gastroenterology* 153(1):98−105

[102] Roth HR, Lu L, Liu J, Yao J, Seff A, et al. 2016. Improving computer-aided detection using convolutional neural networks and random view aggregation. *IEEE Transactions on Medical Imaging* 35(5):1170−1181

[103] Wang H, Liang Z, Li LC, Han H, Song B, et al. 2015. An adaptive paradigm for computer-aided detection of colonic polyps. *Physics in Medicine & Biology* 60(18):7207

[104] Wang P, Liu X, Berzin TM, Glissen Brown JR, Liu P, et al. 2020. Effect of a deep-learning computer-aided detection system on adenoma detection during colonoscopy (CADe-DB trial): a double-blind randomised study. *The Lancet Gastroenterology & Hepatology* 5(4):343−351

[105] Glissen Brown JR, Mansour NM, Wang P, Chuchuca MA, Minchenberg SB, et al. 2022. Deep learning computer-aided polyp detection reduces adenoma miss rate: a United States multi-center randomized tandem colonoscopy study (CADeT-CS trial). *Clinical Gastroenterology and Hepatology* 20(7):1499−1507.e4

[106] Kamba S, Tamai N, Saitoh I, Matsui H, Horiuchi H, et al. 2021. Reducing adenoma miss rate of colonoscopy assisted by artificial intelligence: a multicenter randomized controlled trial. *Journal of Gastroenterology* 56(8):746−757

[107] Ma Y, Wen Y, Lu C, Liao J. 2024. 计算机辅助检测（CADe）与普通肠镜比较识别结直肠腺瘤和息肉效果的 Meta 分析 [Efficacy and safety of computer-aided detection(CADe)in colonoscopy for colorectal neoplasia detection: a meta-analysis]. *中国循证医学杂志 [Chinese Journal of Evidence-Based Medicine]* 24(11):1270−1277 (in Chinese)

[108] Repici A, Badalamenti M, Maselli R, Correale L, Radaelli F, et al. 2020. Efficacy of real-time computer-aided detection of colorectal neoplasia in a randomized trial. *Gastroenterology* 159(2):512−520.e7

[109] Lee MCM, Parker CH, Liu LWC, Farahvash A, Jeyalingam T. 2024. Impact of study design on adenoma detection in the evaluation of artificial intelligence–aided colonoscopy: a systematic review and meta-analysis. *Gastrointestinal Endoscopy* 99(5):676−687.e16

[110] Barclay RL, Vicari JJ, Doughty AS, Johanson JF, Greenlaw RL. 2006. Colonoscopic withdrawal times and adenoma detection during screening colonoscopy. *New England Journal of Medicine* 355(24):2533−2541

[111] Deliwala SS, Hamid K, Barbarawi M, Lakshman H, Zayed Y, et al. 2021. Artificial intelligence (AI) real-time detection vs. routine colonoscopy for colorectal neoplasia: a meta-analysis and trial sequential analysis. *International Journal of Colorectal Disease* 36(11):2291–2303
[112] Ahmad OF, Soares AS, Mazomenos E, Brandao P, Vega R, et al. 2019. Artificial intelligence and computer-aided diagnosis in colonoscopy: current evidence and future directions. *The Lancet Gastroenterology & Hepatology* 4(1):71–80
[113] Maeda Y, Kudo SE, Mori Y, Misawa M, Ogata N, et al. 2019. Fully automated diagnostic system with artificial intelligence using endocytoscopy to identify the presence of histologic inflammation associated with ulcerative colitis (with video). *Gastrointestinal Endoscopy* 89(2):408–415
[114] Jin EH, Lee D, Bae JH, Kang HY, Kwak MS, et al. 2020. Improved accuracy in optical diagnosis of colorectal polyps using convolutional neural networks with visual explanations. *Gastroenterology* 158(8):2169–2179.e8
[115] Zachariah R, Samarasena J, Luba D, Duh E, Dao T, et al. 2020. Prediction of polyp pathology using convolutional neural networks achieves 'resect and discard' thresholds. *The American Journal of Gastroenterology* 115(1):138–144
[116] Patino-Barrientos S, Sierra-Sosa D, Garcia-Zapirain B, Castillo-Olea C, Elmaghraby A. 2020. Kudo's classification for colon polyps assessment using a deep learning approach. *Applied Sciences* 10(2):501
[117] Liu S, Liu X, Chang S, Sun Y, Li K, et al. 2023. Multi-classification of polyps in colonoscopy images based on an improved deep convolutional neural network. *Computers, Materials & Continua* 75(3):5837–5852
[118] Rahman MM, Wadud MAH, Hasan MM. 2021. Computerized classification of gastrointestinal polyps using stacking ensemble of convolutional neural network. *Informatics in Medicine Unlocked* 24:100603
[119] Sinonquel P, Eelbode T, Bossuyt P, Maes F, Bisschops R. 2021. Artificial intelligence and its impact on quality improvement in upper and lower gastrointestinal endoscopy. *Digestive Endoscopy* 33(2):242–253
[120] Zhou J, Wu L, Wan X, Shen L, Liu J, et al. 2020. A novel artificial intelligence system for the assessment of bowel preparation (with video). *Gastrointestinal Endoscopy* 91(2):428–435.e2
[121] Baxter NN, Sutradhar R, Forbes SS, Paszat LF, Saskin R, et al. 2011. Analysis of administrative data finds endoscopist quality measures associated with postcolonoscopy colorectal cancer. *Gastroenterology* 140(1):65–72
[122] National Cancer Center, China, Expert Group of the Development of China Guideline for the Screening, Early Detection and Early Treatment of Colorectal Cancer. 2021. 中国结直肠癌筛查与早诊早治指南（2020，北京） [China guideline for the screening, early detection and early treatment of colorectal cancer (2020, Beijing)]. *中国肿瘤 [China Cancer]* 30(1):1–28 (in Chinese)
[123] Keswani RN, Crockett SD, Calderwood AH. 2021. AGA clinical practice update on strategies to improve quality of screening and surveillance colonoscopy: expert review. *Gastroenterology* 161(2):701–711
[124] Shaukat A, Kahi CJ, Burke CA, Rabeneck L, Sauer BG, et al. 2021. ACG clinical guidelines: colorectal cancer screening 2021. *The American Journal of Gastroenterology* 116(3):458–479
[125] Kaminski M, Thomas-Gibson S, Bugajski M, Bretthauer M, Rees C, et al. 2017. Performance measures for lower gastrointestinal endoscopy: a European Society of Gastrointestinal Endoscopy (ESGE) Quality Improvement Initiative. *Endoscopy* 49(4):378–397
[126] Zhu X, Wu L, Li S, Li X, Zhang J, et al. 2020. 人工智能技术在结肠镜退镜速度实时监控中的应用 [Application of artificial intelligence in real-time monitoring of withdrawal speed of colonoscopy]. *中国消化内镜杂志 [Chinese Journal of Digestive Endoscopy]* 37(2):125–130 (in Chinese)
[127] Lui TKL, Ko MKL, Liu JJ, Xiao X, Leung WK. 2024. Artificial intelligence–assisted real-time monitoring of effective withdrawal time during colonoscopy: a novel quality marker of colonoscopy. *Gastrointestinal Endoscopy* 99(3):419–427.e6
[128] Kawamura T, Wada H, Sakiyama N, Ueda Y, Shirakawa A, et al. 2017. Examination time as a quality indicator of screening upper gastrointestinal endoscopy for asymptomatic examinees. *Digestive Endoscopy* 29(5):569–575
[129] Bisschops R, Areia M, Coron E, Dobru D, Kaskas B, et al. 2016. Performance measures for upper gastrointestinal endoscopy: a European Society of Gastrointestinal Endoscopy (ESGE) Quality Improvement Initiative. *Endoscopy* 48(9):843–864
[130] Jiang YL, Zhao G, Wang SH, Li N. 2025. Leveraging artificial intelligence for clinical decision support in personalized standard regimen recommendation for cancer. *Military Medical Research* 12(1):31
[131] Lu J, Wu Z, Chen J, Jing C, Yu J, et al. 2025. Machine learning-based prediction model for postoperative complications in gastric and colorectal cancer: a prospective nationwide multi-center study. *Chinese Journal of Cancer Research* 37(4):624–638
[132] Gupta P, Chiang SF, Sahoo PK, Mohapatra SK, You JF, et al. 2019. Prediction of colon cancer stages and survival period with machine learning approach. *Cancers* 11(12):2007
[133] Levin TR, Jensen CD, Marks AR, Schlessinger D, Liu V, et al. 2024. Development and external validation of a prediction model for colorectal cancer among patients awaiting surveillance colonoscopy following polypectomy. *Gastro Hep Advances* 3(5):671–683
[134] Shi YH, Liu JL, Cheng CC, Li WL, Sun H, et al. 2025. Construction and validation of machine learning-based predictive model for colorectal polyp recurrence one year after endoscopic mucosal resection. *World Journal of Gastroenterology* 31(11):102387
[135] AI News. 2025. Ping An good doctor launches AI assistant 'Ping An Xin Yi' for 24/7 smart medical consultation. www.aibase.com/news/15705 (Accessed 21 June, 2025)
[136] Zhou J, Zeng Z, Li L. 2021. A meta-analysis of Watson for Oncology in clinical application. *Scientific Reports* 11(1):5792
[137] Ahmad OF. 2021. Early detection of gastric neoplasia: is artificial intelligence the solution? *The Lancet Gastroenterology & Hepatology* 6(9):678–679
[138] Chen F, Su W, Becker SH, Payne M, Castro Sweet CM, et al. 2016. Clinical and economic impact of a digital, remotely-delivered intensive behavioral counseling program on medicare beneficiaries at risk for diabetes and cardiovascular disease. *PLoS One* 11(10):e0163627
[139] Kamitani Y, Nonaka K, Isomoto H. 2022. Current status and future perspectives of artificial intelligence in colonoscopy. *Journal of Clinical Medicine* 11(10):2923
[140] Walradt T, Glissen Brown JR, Alagappan M, Lerner HP, Berzin TM. 2020. Regulatory considerations for artificial intelligence technologies in GI endoscopy. *Gastrointestinal Endoscopy* 92(4):801–806
[141] Karako K, Tang W. 2026. Clinical artificial intelligence (AI) in Japan: Regulatory pathways, domain-specific evidence, and its data infrastructure from an international perspective. *Global Health & Medicine* 8(3):166–181
[142] El-Sayed A, Lovat LB, Ahmad OF. 2025. Clinical implementation of artificial intelligence in gastroenterology: current landscape, regulatory challenges, and ethical issues. *Gastroenterology* 169(3):518–530
[143] Ding P, Gao Z, Zheng C, Chen J, Li K, et al. 2019. Risk evaluation of splenic hilar or splenic artery lymph node metastasis and survival analysis for patients with proximal gastric cancer after curative gastrectomy: a retrospective study. *BMC Cancer* 19(1):905
[144] Wei J. 2024. Advancing the future of gastrointestinal oncology: a call for collaborative excellence. *Gastrointestinal Tumors* 11:e001

Copyright: © 2026 by the author(s). Published by Maximum Academic Press, Fayetteville, GA. This article is an open access article distributed under Creative Commons Attribution License (CC BY 4.0), visit https://creativecommons.org/licenses/by/4.0/.